



## IMMUNOPATHOLOGICAL STUDY ON THE EFFECTS OF VINCRIStINE SULFATE IN WHITE MICE AND RATS

S.H. Muna<sup>1</sup>, Khalil H.AI.Jeboori<sup>1</sup> & A. A. Ban<sup>2</sup>

<sup>1</sup>College of Vet. Medicine/ University of Baghdad, Iraq.

<sup>2</sup>College of Medicine/ University of Baghdad, Iraq.

### ABSTRACT

Chemotherapy widely distributed in this time in the Veterinary and Human Medical application in order to achieve successful cancer and viral diseases treatment with other medical uses. Vincristine (VCR) considered as member of chemotherapeutic drugs used in treatment most of lymphoid and haemopoietic systems cancers types. The pathological study pointed to study; (Spleen, Lung, Liver, Kidney, Brain, Gastro-Intestinal-Tract, Skin).Organs changes in mice. The immunological study pointed to evaluate the immune state (humoral and cellular immunity) after treatment with Vincristine as alone or accompanied with Specific Antigen (Brucella Vaccine) in mice and rats .So we have to divide the experimental animals in to two main group first one (non immunized group) and second one (immunized group). Results showed that there were pathological changes reported after 2weeks of two different treatment (immunized and non immunized) in all investigated organs .And immunosuppressant effects on ; IgM and INF- $\gamma$  and lymphoid T-cell markers (CD4+ and CD8+ )appear also at 2weeks after two different treatments. The Vincristine had non-specific toxic effect so caused in appearance of pathological lesions as well as caused in signs of immunosuppressant's effects on cellular and humoral immunity.

**KEY WORDS:** Vincristine, rat, mice, immunity, pathology.

### INTRODUCTION

Vincristine therapy induced non-selective cytotoxicity that results in moderate myelosuppression, intestinal disturbances, alopecia, peripheral and rarely central toxicity [1-4]. Although VCR is widely used in small animal clinical oncology several agents have been used in association to decrease its bone marrow cytotoxicity. [5,6]. VCR penetrates the blood-brain-barrier poorly, so alternate chemotherapeutic agents may be required for CNS Leukemia. In general the important side effects are:

1. Hepatic Impairment: impairment of hepatic function or jaundice may warrant dosage adjustments, as VCR is metabolized in the liver and excreted in the bile [7,8].
2. Respiratory distress: syndrome has been reported following the administration of VCR up to 2 wk following treatment. The most common adverse reaction is hair loss and the most troublesome reactions are neuromuscular in origin [9].
3. Neuromuscular neurotoxicity: this is the most common dose-limited side effect due to sensory impairment and paraesthesia with further treatment neurotic pain may develop & later motor difficulties. Convulsions, accompanied by hypertension have been reported, ataxia, loss of deep-tendon reflexes, foot drop, cranial nerve palsy paralysis, jaw pain ,pharyngeal pain, parotid gland pain, bone pain, back pain, limb pain, myalgias and numbness of the digits have been observed. Transient cortical blindness and optic atrophy also have been reported together with sympathetic neuropathy. [10,11]
4. Pulmonary: At 1st 2wk of treatment, respiratory distress has been development [12].

5. Hypersensitivity: rash of allergic type reactions, such as anaphylaxis, Rash and edema that are temporally related to VCR therapy [12].
6. Haematologic disorder: at normal doses reports of leucopenia, anemia & thrombocytopenia are occasionally seen [12].
7. Gastrointestinal disorder constipation and paralytic ileus are not uncommon and are frequently associated with abdominal cramps [12].
8. Urogenital disorder: Hyperuricaemia develops in some patients with non-Hodgkin's lymphomas or leukemia giving VCR, and impair of fertility and embryocidal and teratogenic in mice, rats, hamsters , rabbits and monkeys in very low dosages ( 0.05mg /kg ).Infertility and azoospermia in men as well as amenorrhea in women [13].
9. Dermatological disorder: Alopecia occurring in 20-70% of patients it's, reversible upon discontinuation of the drug rash and photosensitivity reaction have also been reported [14].
10. Endocrine disorder: Hyper secretion of ADH antidiuretic hormone has been reported after VCR treatment [15].
11. Cardiovascular disorder: Hypotension and hypertension, coronary artery disease, myocardial infarctions have been associated with therapy that included VCR [6].
12. Others: fever, defective seating myoclonic jerks ,abnormal valsava response weight loss , malaises, dizziness, skin reactions , dyspnea, bronchospasim , impotence , diminished libido. In monkeys, single injection of VCR at a dose of (0.15-0.175) mg/kg on a day 27or 29 of gestation produced one fetus with encephalocele (Skull defect) and one with syndactyly

(webbing of fingers or toes). In rats single injection of VCR at dosage of (0.05-0.075) mg/kg on day 9 of gestation produced highly incidence of eye defects and some microcephaly and neural tube closure defects [16,17].

#### Effect of Vincristine sulfate on immune response

VCR is cytotoxic agent that bind to cellular cytoskeleton is microtubules and so cause disruption of mitotic process during cell division lead to blocking cell growth, proliferation, cell division, mostly rapidly dividing cells as lymphocytes [18, 19]. The main feature of VCR effects on rapidly dividing cells are marked leucopenia, erythrocytopenia neurotoxicity [19-21] showed that VCR caused marked releasing of markers (CD<sub>4</sub> & CD<sub>8</sub>) on normal and leukemic T-cells' surfaces and described that effects as immune suppresser effects. Also [22] revealed that VCR induced inhibition of INF-gamma release from rodent splenocytes [19] said that VCR exhibit decreased augmentation of primary antibody response *i.e.* was exhibited an immune depressing effect after enhancing the primary Abs response against any specific Ag inoculation [23] revealed that immunization of mice and rats with proper dose of an Ag stimulus lead to T-cell proliferation and Abs response of circulating lymphocytes and when later exposed to VCR, the immunized mice and rats show immunosuppressant effects and the same effects appeared on the un immunized mice was subjected to VCR. [24,25] revealed that VCR cause inhibition of release some type of interleukins in mice and rat. Also author [26] showed that VCR treatment in dog with TVT can cause transient lymphopenia after one day of treatment. VCR cause marked inhibition in lymphocyte proliferation characterized by suppression of DTH and primary Abs production and inhibition of inflammatory processes and depression of small medium; large lymphocytes in peripheral Blood cells [26].

#### MATERIALS & METHODS

**Animal grouping and treatments:** Mice were divided as following:

**1st experimental group (none immunized):** were 20 male mice at, this 1st group was subdivided in to 4 subgroup each one contain four mice injected with. (0.1mg/10gmBW) I/P twice weekly at four separated intervals.

**2nd experimental group (immunized):** 20 male mice were subdividing to 4 subgroup each one contain four mice injected with. (0.1mg/10gmBW) I/P twice weekly at four separated intervals and Ag (0.2 ml/mouse) 2dose S/C.

**3rd experimental group:** A control group 20 male mice of the same age were not treated unless distilled water.

**Rats were also divided into 3 sub groups**

**1st experimental group (none immunized):** contains 8 male rats subdivided to four subgroup each one contain two rats, injected with VCR (1mg/kg/BW) I/P twice weekly at four separated intervals.

**2nd experimental group (immunized):** contains 8 male rats subdivided to four subgroup each one contain two rats, injected with VCR (1mg/kg/BW) I/P twice weekly at four separated intervals and Ag (0.8ml/rat) 2 dose S/C.

**3rd experimental group:** A control group 4 male rats of the same age were not treated unless distilled water.

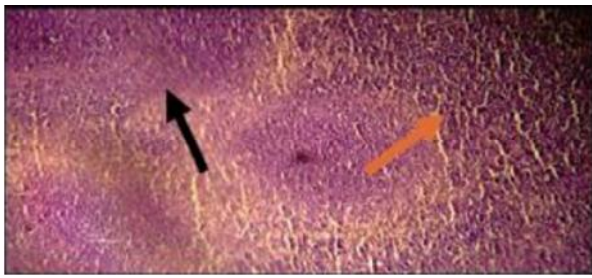
#### RESULTS & DISCUSSION

##### Results of pathological study

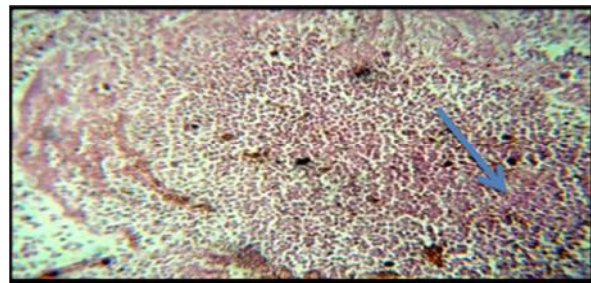
The first and second groups of animals showed pathological lesion as showed in tissue sections. Immune tissue showed follicular hyperplasia and haemosedrin (fig.1&2), Liver showed hepatocytes' degenerated changes and necrosis (fig.3&4), Lung showed pneumonia and necrosis (fig.5&6), Kidney showed necrosis (fig.7&8). GIT showed vacuolation and necrosis (fig.9). Brain showed gliosis (fig.10). Skin showed abnormal keratinization and alopecia (fig.11).

The results of pathological finding in this study, agreed with authors [27-29] Opinions was that the Vincristine is a member of drugs called spindle inhibitors, caused impairment of cellular growth and DNA synthesis processes which lead to mitotic block, that's responsible for pathological changes. The pathological finding on immune tissues agree with author [30] Who explained that VCR is a cytotoxic drug and agreed with authors [23,26] opinions. The results of general pathological and degenerative changes of Braine after VCR treatment agreed with [10] who pointed that the increased risk of Vincristine neurotoxicity associated with low cyp3 A5 expression genotype in humans' study. And agreed with [11] in animals. The pathological finding of inflammatory infiltration agreed with [31, 32], who explained that VCR treatment induced marked inflammatory infiltration about 9 day after administration. The pathological finding of GIT after VCR treatment in line with [33,34] who found that rodent treated with VCR induced early signs of GIT inflammation with marked changes in the glandular region. Pathological changes on liver agreed with authors' (35; 36) opinions. Kidney changes agreed with [37]. Lung changes agreed with authors' [38,39] opinion in general and with [40] opinion in particular rodent study. Skin changes agreed with [41-44] who said that the most pathological finding induced in animals after 28 hrs to several wks of treatment with VCR.

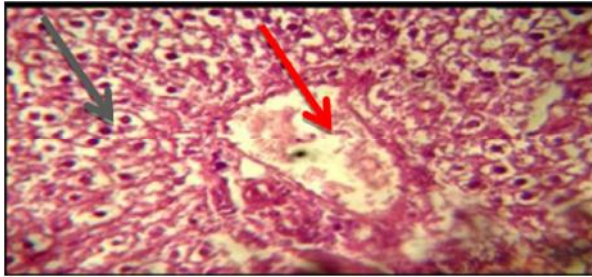
The results of VCR effects on humoral immunity agreed with [45] who showed that VCR treatment to patient with acute myeloid leukemia, induced rapid immunoglobulin dropped level ( IgA, IgM, IgG) and agree with [46] who explained that treatment of VCR in vivo and in vitro in rodent, caused marked inhibition of release of (IgM, INF- $\gamma$ ). As well as agreed with [47] Who showed that VCR injection to rodent at 0.1 mg/kg B.W I/P dose, against specific Ag (Bovine serum albumen) caused inhibition of Ab formation and DTH and he explained that VCR exert it's immune suppressive effects by inhibiting synthesis of the RNA template (messenger-RNA); DNA synthesis; lipids biosynthesis; cycling nucleotides metabolism; glutathione metabolism; calmodulin dependant Ca<sup>2+</sup> transport ATPase, which were important in maintenance of normal immune response. The results of CD4 and CD8 reduction agreed with [48-51], who showed that VCR treatment as a chemotherapeutic agent resulted in early decrease in CD4:CD8 ratio within few hours-day. and revealed that CD4 T-cells dropped from a mean of 588  $\pm$  76 / mm<sup>3</sup> before chemotherapy to 105  $\pm$  28/mm<sup>3</sup> (p=0.0002) and CD8 T-cells dropped from a mean of 382  $\pm$  41/ mm<sup>3</sup> to 150  $\pm$  46/ mm<sup>3</sup> during chemotherapy using test of flow cytometry.



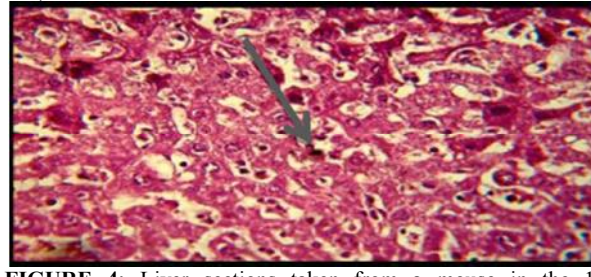
**FIGURE 1:**Spleen from a mouse in the 1st experimental group: showing reactive follicular hyperplasia of red pulp(black arrow) and para-follicular hyperplasia (blue arrow) after 4wk treatment with VCR alone.(H&E X100).



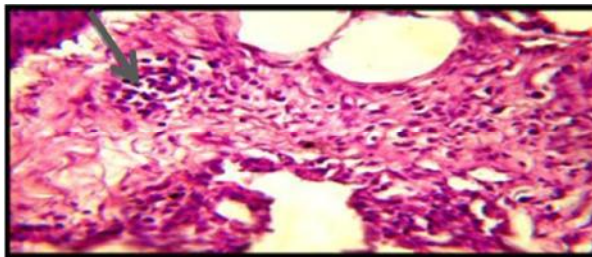
**FIGURE 2:** A section of cervical lymph node of a mouse in the 2nd experimental group: showing Para follicular hyperplasia of white pulp (black arrow)&haemosiderin depositing(blue arrow). After 4wk until last 8 wk treatment with VCR &Ag. (H&E X 100).



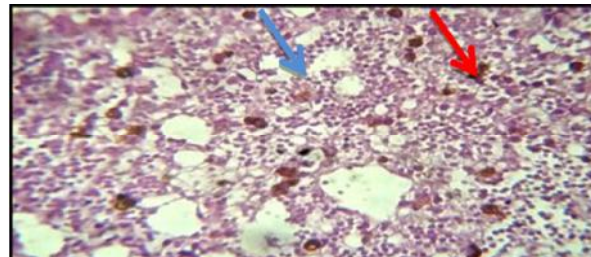
**FIGURE 3:** Liver section taken from a mouse in the 2nd experimental group: showing marked loss of sinusoidal spaces with swelling and vacuolated hepatocytes from hydropic degeneration (black arrow) with congested C.V (red arrow) after 4 wk of treatment with VCR &Ag.(H&E.X400).



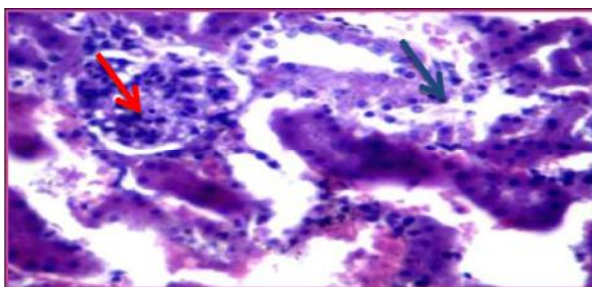
**FIGURE 4:** Liver sections taken from a mouse in the 1st experimental group: showing marked loss of sinusoidal Spaces with swelling and vacuolated hepatocytes from hydropic degeneration (black arrow) and loss of normal Architecture of hepatic tissue, after 6th & 8th wk of treatment with VCR alone. (H&E.X400).



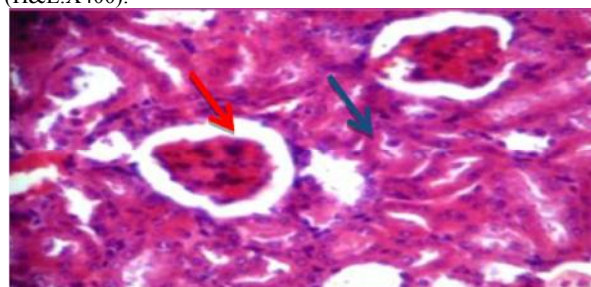
**FIGURE 5:** Lung section taken from a mouse in the 1st experimental group: showing chronic Interstitial Pneumonia represented by inflammatory infiltration (black arrow) with mucofibrinous exudation within emphysematous alveoli (blue arrow) after 8 wk of treatment with VCR alone. (H&E.X400).



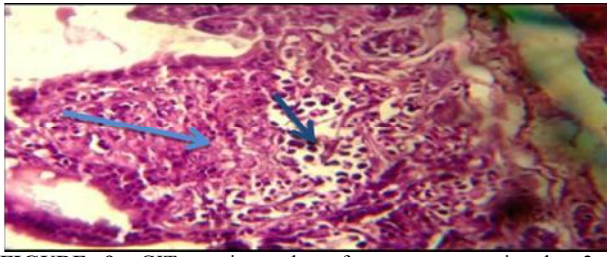
**FIGURE 6:** Lung section taken from a mouse in the 2nd experimental group: showing inflammatory infiltration (black arrow) with extensive necrosis (blue arrow) & haemosiderin deposition (red arrow) after 8 wk of treatment with VCR&Ag (H&E.X400).



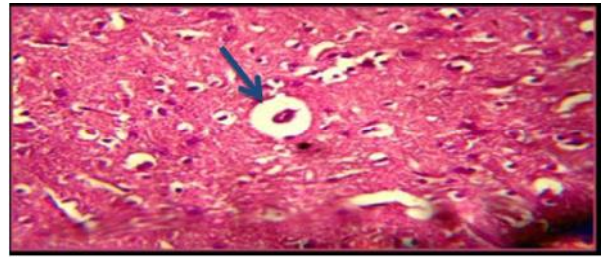
**FIGURE 7:** Kidney section taken from a mouse in the 1st experimental group: showing enlargement of glomeruli size (red arrow) with necrosis of proximal tubules &inflammatory cells (black arrow), after 6 wk of treatment with VCR alone.(H&E.X400).



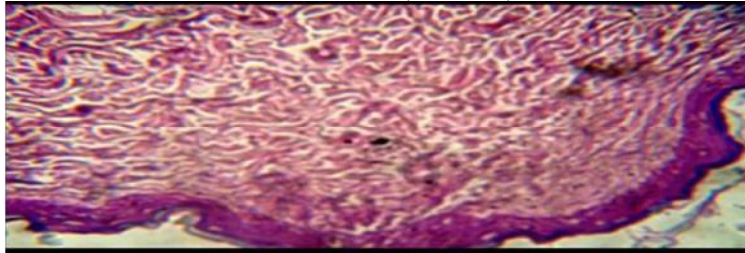
**FIGURE 8:** Kidney section taken from a mouse in the 2nd experimental group: showing enlargement of glomeruli space (red arrow) with necrosis of proximal tubules (black arrow), after 6 wk of treatment with VCR &Ag. (H&E. X400).



**FIGURE 9:** GIT section taken from a mouse in the 2nd experimental group: showing inflammatory infiltration with hydropic degeneration (black arrow) and necrosis (blue arrow) after 8 wk of treatment with VCR and Ag . (H&E.X100).



**FIGURE 10:** A section of a brain from a mouse in the 2nd experimental group showing: vacuolation with perinuclear edema (arrow) after 6wk of treatment with VCR and Ag. (H&EX400).



**FIGURE 11:** A section of skin of back, from a mouse in the 2nd experimental group showing : complet loss of hair follicals with parakeratosis, at the end of 6wk of treatment with VCR and Ag.(H&EX100).

**Results of immunological study: 1- Humoral immunity**

**TABLE 1:** showed level of (IgM) in mouse serum in 1<sup>st</sup> and 2<sup>nd</sup> experimet groups

Group- Treatment N=5	IgM mean ± SD (ng/ml)/Mouse	
	1 <sup>st</sup> exp. group (non immunized) treated with (0.1mg/10gm.b.w)VCR I/P from 2-8 weeks	2 <sup>nd</sup> exp. group (immunized) treated with (0.1mg/10gm.b.w)VCR I/P from 2-8 weeks with Ag treatment (0.2ml/mouse) S/C 2dose
2 weeks	0.333 ± 0.08 a A	0.345 ±0.10 a A
4 weeks	0.201 ± 0.6 a A	0.223 ± 0.06 a A
6 weeks	0.152 ± 0.02 a A	0.155 ± 0.02 a A
8 weeks	0.022 ± 0.09 a A	0.025 ± 0.07 a A
control	0.383 ± 0.05	0.383 ± 0.05

Small letters denotes that differences significantly between 1<sup>st</sup> and 2<sup>nd</sup> subgroups (p <0.001)  
Capital letter denotes that significant differences between each time of treatment (p <0.05)

**TABLE 2:** showed level of mouse (INF-γ) in 1<sup>st</sup> and 2<sup>nd</sup> experimental groups

Group- Treatment N=5	INF- γ mean ± SD (pg/ml) Mouse	
	1 <sup>st</sup> exp. group (non immunized) treated with (0.1mg/10gm.b.w)VCR I/P from 2-8 weeks	2 <sup>nd</sup> exp. group (immunized) treated with (0.1mg/10gm.b.w)VCR I/P from 2-8 weeks with Ag treatment (0.2ml/mouse)
2 weeks	0.458 ± 0.08 a A	0.473 ±0.07 a A
4 weeks	0.312 ± 0.05 a A	0.322 ± 0.03 a A
6 weeks	0.139 ± 0.25 a A	0.246 ± 0.14 a A
8 weeks	0.077 ± 0.154 a A	0.095 ± 0.327 a A
control	0.527 ± 0.08	0.527 ± 0.08

Small letters denotes that differences significantly between 1<sup>st</sup> and 2<sup>nd</sup> subgroups (p <0.001)  
Capital letter denotes that significant differences between each time of treatment (p <0.05)

**TABLE 3:** CD4 ratio in spleen of rates in 1<sup>st</sup> experimental group (non immunized)

Group- Treatment N=2	Score 1% (rats)	Score 2% (rats)	Score 3% (rats)
2 weeks	0 A	50% (1) A	50% (1)
4 weeks	100% (2) A	0	0 A
6 weeks	100% (2)	0 A	0 A
8 weeks	100% (2)	0 A	0 A
Control N=4 rats	0	0	100% (4)

Capital letter denotes that significant differences between each time of treatment (p <0.05)

**TABLE 4:** CD4 ratio in spleen of rates in 2<sup>nd</sup> experimental group (immunized)

Group- Treatment N=2	Score 1% (rats)	Score 2% (rats)	Score 3% (rats)
2 weeks	50% (1) A	50% (1) A	0
4 weeks	50% (1) A	50% (1) A	0 A
6 weeks	100% (2) A	0 A	0
8 weeks	100% (2)	0 A	0
Control N=4 rats	0	100% (4)	0

Capital letter denotes that significant differences between each time of treatment (p <0.05)

**TABLE 5:** CD8 ratio in spleen of rates in 1<sup>st</sup> experimental group (non immunized)

Group- Treatment N=2	Score 1% (rats)	Score 2% (rats)	Score 3% (rats)
2 weeks	0 A	100% (2) A	0 A
4 weeks	0 A	50% (1) A	50% (1) A
6 weeks	50% (1) A	50% (1) A	0 A
8 weeks	100% (2) A	0 A	0 A
Control N=4 rats	0	50% (2)	50% (2)

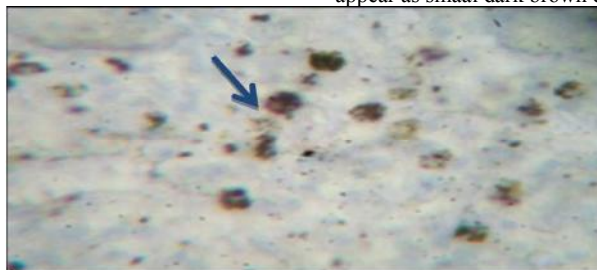
Capital letter denotes that significant differences between each time of treatment (p <0.05)

**TABLE 6:** CD8 ratio in spleen of rates in 2<sup>nd</sup> experimental group (immunized)

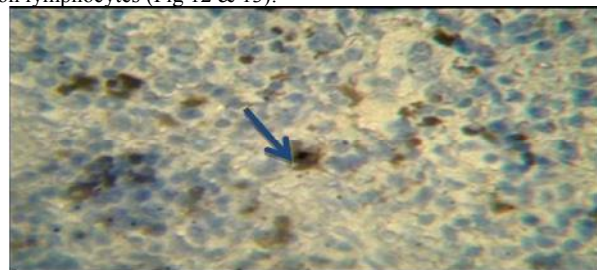Group- Treatment N=2	Score 1% (rats)	Score 2% (rats)	Score 3% (rats)
2 weeks	0 A	0 A	100% (2) A
4 weeks	0 A	100% (2) A	0 A
6 weeks	100% (2) A	0 A	0 A
8 weeks	100% (2)	0 A	0 A
Control N=4 rats	0	50% (2)	50% (2)

Capital letter denotes that significant differences between each time of treatment (p <0.05)

Results of Microscopically Apperances of CD4+ and CD8+: In 1<sup>st</sup> and 2<sup>nd</sup> experimental groups of rats picture of CD4+ and CD8+ appear as smaal dark brown dot on lymphocytes (Fig 12 & 13).



**FIGURE 12A:** section in a spleen from a rat in the 1<sup>st</sup> experimental group after 2 wk of treatment with VCR alone: showing CD4+ & CD8+ marker as small dot on lymphocytes (arrow). (Oil.X1000)



**FIGURE 13 A:** section in a spleen from a rat in the 2<sup>nd</sup> experimental group after 2 wk of treatment with VCR & Ag: showing CD4+ & CD8+ marker as small dot on lymphocytes (arrow). (Oil.X1000).

**REFERENCES**

- [1]. ZinZani, P.L., Pulsoni, A., Perrotti, A., Soverini, S., Zaja, F., De Renzo, A., Stori, S., Lauti, V. M. (2004) Chemotherapy for patients with follicular lymphoma *J. Clin. Oncol.* 22: 2654-2661.
- [2]. Whittaker, J. A., Parry, D. H., Bunch, C. (1998) Coma associated with vincristine therapy. *Br. Med. J. V. 4. P.335-337.*
- [3]. Hamilton, T. A., Cook, G. R., Braund, K. G. (1991) Vincristine induced peripheral neuropathy in dog *J. Amer. Vet. Med. Assoc.*:635-638.
- [4]. Cuddon, P. A. (2002) Acquired canine peripheral neuropathies *Vet. Clin. Amer. Sma. Anim. pract. V. 32 : 207-249.*
- [5]. Mcknight, J.A. (2003) Principles of Chemotherapy . *Clin . Tech. Small. Anim. Pract.* V.18, P: 67-72.
- [6]. Martins, D.B., Lopes, S.T.A. Mazzanti, C. M. R. Spanevello, R. Schmatz ,M., Correa, N. (2011) Lipid peroxidation in rats treated with Vincristine Sulphate and nandrolone deaconate: Pharmacology Study. *Arg. Bars, Med Vet. Zootec. Vol. 63. No.1 Biol. Horizonte Feb. 2011.*
- [7]. King Roger (2006) *Cancer Biology.* Essex, England: Pearson, Education. PP.146.
- [8]. Upamanyu, R.,Yogosh, S., Jyoti, D. (2011 ) Effects of Vincristine on the bile flow in male Albino Rats , *Indian, J. Physiol. Pharmacol.* 55(2):101-9.
- [9]. Perez, E. A. (2009) Microtubules inhibitors: Differentiating tubulin inhibiting agents based on mechanisms of action, Clinical activity and resistance. *Mol. Can. Therap.* 8:2086-2095.
- [10]. Egbelakin, A. (2011) Increased of Vincristine neurotoxicity associated with low CYP3A5 expression genotype in children with acute lymphoblastic leukemia *pediatr. blood cancer*, 56: 361-367.
- [11]. Eillyad Issabeagloosajgadhejazi, mohammad taghizadieh (2011) study of Vincristine effect in the gestation period on mice cerebellum formation *advances in Environmental Biology*, 5(7): 1960-1964.
- [12]. Cave, T.A., Norman, P., Mellor, D. (2007) Cytotoxic drug use in treatment of dogs and cats with cancer by U.K *Vet. Practices J., Small Anim. Pract.* V. (2003 to 2004) 48: 371-377.
- [13]. Arnon, J., Meirou, D., Lewis, R., Ornoy, A. (2012) genetic and teratogenic effect of Cancer treatment on gametes and embryos. *Oxf. J.* 7(4): 394-403.
- [14]. Jousephin, A., McKnight, B.S.C. (2005) Principles of chemotherapy. *Animal Medical Center .Clinical Techniques in small Animal Practice*, 8(2): 67-72 *Med. Oncol.*
- [15]. Tiejuncheng, Qingliang Li, Yanli Wang, and Stephen H. Bryant (2011) *Drugs Chemical information and modeling.* 51 (9):2440- 2448.
- [16]. Heywood V.H. (2008). *Flowering plant families of the world.* Royal Botanic Gardens, kew.
- [17]. *Vet.help.com.* (2011) Vincristine sulfate: Veterinary term : diagnosis and drug hand book on line ©.2011
- [18]. Lanfranch A., Andolina M., Tettonik P.F., Locatelli F., De Manzini A., Candott F., Albertini A. (1992) Functional depletion of T cells by Vincristine as an in vitro model for the prevention of graft versus host disease . *J. Heamatolo.* 77: 11-5.
- [19]. Randall J. Byred (1981) Immunopotentiating effect of vincaalkaliode on the Autibody Response to sheep Red blood cells in the mouse *J. Nat. Med. Asso.*, 73(8): 551-555.
- [20]. Lehrnbecher, T., Oster, C., Vazquez, C. Mackall and Chanock, S. (1997) Chemotherapy-induced alterations in host defense in children receiving therapy for cancer *J., pediatr Hematoloncol.* 19: 399-417.
- [21]. Eloisic, L., Glanda, E., Poula, A., Silivia, V., Mariama, G., Elida, A. and Silvia, E.H. (2008) Dissimilar invasive and metastatic behavior of Vincristine and doxorubicin resistant cell line divided from a murine T-cell lymphoid leukemia. *J.Clin. and Exper. Metas.* 19 (4): 283-220.
- [22]. Khalid Ahmed and John L. Turk (2011) *Cancer Immunology Immunotherapy*, 28(2): 87-92.
- [23]. Winston Vasudevan, D. M. (2003) Effects of Vincristine on lymphocytes proliferation. *Indian J. Clinical Bioch.* 18 (2): 161-168.
- [24]. Norikaazu, K., Takehiko, M., Yuka, K., Toshikazu, K., Masanobu, O., Shiroh, K. (2008) The critical role of invading peripheral macrophage-derived interleukin-6 in Vincristine- induced mechanical allodynia in mice. *Eur. J. of Pharm. V.* 592, Issue (1-3), 11 Sept. Pp: 87-92.
- [25]. Ahmed, K., Vander meide, P.H., Turk, J.L. (1989) Effect of anticancer drugs on the release of Interferon gamma (INF-γ) and antibody in vitro and invivo. Department of pathology, Royal College of Surgeons of England London, U.K, *Can. Immun. Ther.* 1989. 30(4):213-8.
- [26]. Medleau, L., Dawe, D.L., Clavert, C.A. (2010) Immunosuppressive effects of Cyclophosphamide, Vincristine , and L-asparagines in dogs. *Am. J. Vet. Res.* 44 (2): 176-80.
- [27]. Giulia, S. (2011) Vinca alkaloids: Molecular Mechanism .*Oxford J.V.* 2011, Issue 43 :54-55.
- [28]. Longuet, M. Serduc, R., Riva, C. (2004) Implication of bax in apoptosis depends on microtubule network mobility" *IntJ.Oncol.* 2004 Aug, 25(2): 309-17.
- [29]. Ozalp, G., Zik, B., Bastan, A., Pekers, O.E., Baskan, I., Darbaz I.S. karakas (2012) Vincristine modulates the expression of Ki 67 and apoptosis in naturally occurring Canine Transmissible Venereal Tumor (TVT). *Biotech Histochem.* 87(5): 325-30 .
- [30]. Xianghou, W., Dong-Yan, T., Hing, L.W., Huichen, F., Young-Chuan, W., and SaiWah, T. (2003) Vincristine is associated with mitotic arrest and Raf/Bcl-2 phosphorylation in nasopharyngeal carcinoma cells: Immun path study. *Origen Paper; Oncogen* vol. 2003 No.22:109-116.
- [31]. Riccardi, A., Montecucco, C., Cresci, R., Traversi, E., Peruginis (1998) Effect of Vincristine on the

- bone marrow cells and other organs in Patients with multiples myeloma: a cytomorphologic study. *Tumori*. J.12 (1)43-56.
- [32]. Saunders V. Kumar, Aul. Abbas, Jon C. Astes (2013) *Robbins' Basic Pathology*.9th.ed Elsevier, Pp:10-244.
- [33]. Johanson, I. S., Armstrong, J. G., Gorman, M., Burnett, J. P. (1998) "The Vinca alkaloids: A new class of oncolytic agents" *Can. Res.* Septem. 23 (8 part 1): 1390-427.
- [34]. Harmon, B.V., Takemato, S., Winter Ford, C.M., Potten, C.S. (2008) Cell death induced by Vincristine in Gastrointestinal Crypts of mice and a human Burkett's' lymphoma cell line. *Cell. Proliferation* 5<sup>th</sup>.ed. 25:523-536.
- [35]. Rassat, J., Robenek, H., Themann, H. (1981) Ultra structural alteration in the mouse liver following Vincristine administration. *Exp. Pathol.* 1981, 20(3): 163-74.
- [36]. Upmanyn, R., Dwiedi, J, Saxena, Y. (2009) Hepatotoxic effects of Vincristine: an experimental study on albino rats. *Indian J Physiol Pharmacol*.31 (3):123-127.
- [37]. Hejazi Sajjad (2012) Study of nephrotoxic effects of Vincristine treatment in mice.Scholars Research Library. *Annals of Biological Research*, 2012, 3 (5):2304-2306.
- [38]. David, O. Slauson, Barry J. Cooper (2002) *Mechanisms of Disease: a textbook of general pathology*. 3<sup>rd</sup> ed. Publishing Director: Linda L. Duncan .U.S.A. Pp: 379-416.
- [39]. Donald, M. McGavin, James F. Zachary (2007) *Pathological Basis of Veterinary Disease*.4th ed. Publishing Director: Linda L. Duncan .U.S.A. Pp: 463-558.
- [40]. William, W. Au., Paul Bibbins, Jonathan, B. Ward Jr., Marvin, S. Legator (1988) Effects of Vincristine on lung: an experimental study in mouse and hamster. The University of Texas Medical Branch, Department of Preventive Medicine and Community Health, Division of Environmental Toxicology, Mutation Research Letters. U.S.A., 208(1):1-7.
- [41]. Dorr, R.T., Alberts, D. S. (1996) Vinca alkaloid skin toxicity: antidote and drug disposition studies in the mouse. *J Nat. Can. Inst. from Cancer Chemother. Pharm. Sprin. Verlag.* (1996) 37: 351-355.
- [42]. Tritsh, H., and Pappas, A. (1997) Mitosis blocked in dermis and Epidermis during Vincristine sulfate treatment. *Journal of Molecular Medicine*, 489 (15): 950- 951.
- [43]. Withrow, S. J. and McEwen, E. G. (1996) *Small animal clinical oncology* 2ed Philadelphia: WB Saunders co. USA.
- [44]. Hiller, K., Meyer, P. and Wilms, K. (2011).In vivo cell kinetic effects of Vincristine on the spontaneous AKR leukemia: Recruitment of non proliferating cells.*Blut.*©Springer-Verlag.,45(1):39-45.
- [45]. Al-Aahmed Hazim I. A. (2010) Effect of Vincristine on Immunoglobuline-M (IgM) in patients with acute myeloid leukemia. *Med. J. of Ticrit Univ.* (1) N.141:146-151.