



PREDICTIVE EFFICIENCY OF ULTRASOUND SCANNING AND PLASMA PROGESTERONE ASSAY FOR DETECTION OF EARLY PREGNANCY AND EMBRYONIC MORTALITY IN CATTLE

K.K. Hadiya, A.J. Dhami*, B.B. Nakrani, J.A. Patel & N.P. Sarvaiya

Department of Animal Reproduction Gynecology & Obstetrics, College of Veterinary Science and Animal Husbandry

Anand Agricultural University, Anand-388 001, Gujarat, India

*Corresponding author email: ajdhami@aau.in

ABSTRACT

The purpose of this study was to know the predictive efficiency of ultrasound scanning between day 23 and 42, and plasma progesterone assay on day 21 post-AI for detection of early pregnancy and embryonic mortality in zebu and crossbred cows. Sixty (24 normal cyclic and 36 infertile induced cyclic) inseminated Gir and crossbred (HFxK) cows that did not return to estrus by day 21 post-AI were utilized for transrectal ultrasound scanning of uterus four times, *i.e.* on day 23, 28, 35 and 42 using 6.5 MHz frequency linear array transducer to detect early pregnancy and embryonic mortality, if any. The findings were correlated to plasma progesterone profile on day 21 post-insemination. The sensitivity of ultrasound scanning was 100 % on all the 4 days. The specificity was lower on day 23 and 28 (68.00 % each) as compared to day 35 (92.00 %) and 42 (100%). On day 23 and 28, 8 animals were incorrectly diagnosed pregnant, while the corresponding figures on day 35 and 42 were two and zero respectively. However, the progesterone assay on day 21 post-AI revealed 9 animals being diagnosed pregnant incorrectly. The sensitivity and negative predictive values were 100 % on all 4 days by both the methods, but specificity and positive predictive values were lower for pregnancy diagnosis using progesterone assay (64.00 % and 79.55 %) as compared to ultrasound scanning results on all 4 days (day 23 & 28, 68.00 and 81.40 % each; day 35, 92.00 and 94.59 % and day 42, 100% each). Similarly, the accuracy was comparatively higher with ultrasound scanning on day 35 and 42 than the progesterone assay (96.67 & 100 % vs 86.44 %). Based on plasma progesterone profile on day 21, 9 animals were incorrectly diagnosed as pregnant (P_4 , 4.14 ± 0.12 ng/ml) when confirmed on day 60 by rectal palpation. There was early embryonic mortality in three animals (3/35; 8.57%) between day 28 and 35 post-breeding. Technique of ultrasound scanning facilitated the diagnosis of all non-pregnant animals as early as on day 23 post-service. This is an advantage over the technique of rectal palpation for pregnancy diagnosis, where it is not possible to get 100 % reliable result so early in non-pregnancy. The specificity, positive predictive value and diagnostic accuracy were comparatively higher on days 35 and 42 post-service, indicating that day 35-42 is the earliest possible time when pregnancy diagnosis should be attempted using ultrasound for maximum accuracy and specificity in cattle.

KEY WORDS: Cows, Early pregnancy diagnosis, Ultrasonography, Progesterone assay, Detection of embryonic mortality.

INTRODUCTION

The successful mammalian reproduction encompasses the ability to mate, the capacity to conceive and carry the fetus and deliver a viable young one at the end of the normal gestation. A novel way to reduce calving to conception interval in dairy animals is the early pregnancy diagnosis and early detection of those animals that have not conceived after service (Pieterse *et al.*, 1990). Ultrasonography has been successfully used for early pregnancy diagnosis as well as for detection of early embryonic mortality in cattle (Totey *et al.*, 1991; Patel *et al.*, 2005). Higher embryonic mortality has been reported to be one of the major causes of repeat breeding. An incidence of 20-50 per cent embryonic and foetal death has been noticed in apparently normal healthy animals of all domestic species including bovines (Arthur *et al.*, 1989). Patel *et al.* (2005) recorded 15 % early embryonic mortality between day 23 and 29 in repeat breeding HF cows using USG and P_4 profile. This study was aimed to detect and correlate the findings of early pregnancy

diagnosis and embryonic mortality by plasma P_4 on day 21 and trans-rectal ultrasound scanning on day 23, 28, 35 and 42 post-insemination with 60 days rectal palpation in Gir and crossbred cows.

MATERIALS & METHODS

The present study was carried out in the herd of Gir and crossbred cows of Livestock Research Station, AAU, Anand. A total of 60; 24 normal cyclic and 36 infertile induced cyclic Gir and crossbred cows not returned to estrus by day 21 post-insemination were selected for detection of early pregnancy and/or early embryonic mortality through plasma P_4 and ultrasound scanning. The ultrasound examinations were first performed on day 23 using a real-time B-mode ultrasound scanner (M5 Vet, Mindray, China) equipped with a 6.5 MHz linear array transrectal transducer. Faecal material was removed from the rectum before inserting the transducer. Those cows found pregnant were further scanned on day 28, 35 and 42 to detect the embryonic vesicle and embryo proper. The

location of CL on ovary was determined through per rectal palpation and then rectal probe was positioned in close proximity to the dorsal surface of the uterine horn, ipsilateral to the ovary containing CL. After initial orientation, ipsilateral uterine horn was scanned on its dorsal and then on lateral surface for signs of pregnancy. Desired images were frozen on the screen and hard copies (sonograms) were taken using videographic thermal printer. Positive diagnosis of pregnancy was based on the presence of a non-echogenic round area of varying size in the lumen of an echogenic uterine horn representing the fluid filled allantoic cavity termed as embryonic vesicle (Pierson and Ginther, 1984; Pieterse *et al.*, 1990). The correct and incorrect diagnosis of pregnancy was defined as per Patel *et al.* (2005). Early embryonic mortality was confirmed looking to changes in the uterine content and loss of fetal fluid from the uterus previously found gravid in relation to actual status confirmed per rectum 60 days

post-AI. Diagnostic accuracy, positive predictive value and negative predictive value of the methods were defined as per the guidelines of Badtram *et al.* (1991). The findings of ultrasound scanning were correlated to plasma progesterone profile on day 21 post-AI.

RESULTS & DISCUSSION

The frozen ultrasound images -sonograms- of embryonic vesicles and/or embryonic loss recorded on day 23, 28, 35 and 42 post-breeding are depicted in Figure 1. It was possible to clearly visualize the embryonic vesicle in every animal that was found pregnant on all days of scanning. The sensitivity, specificity, positive predictive value, negative predictive value and accuracy of pregnancy diagnosis observed at an early stage by ultrasound scanning and plasma progesterone concentration on day 21 post-AI are presented in Table 1 and in Histogram 1.

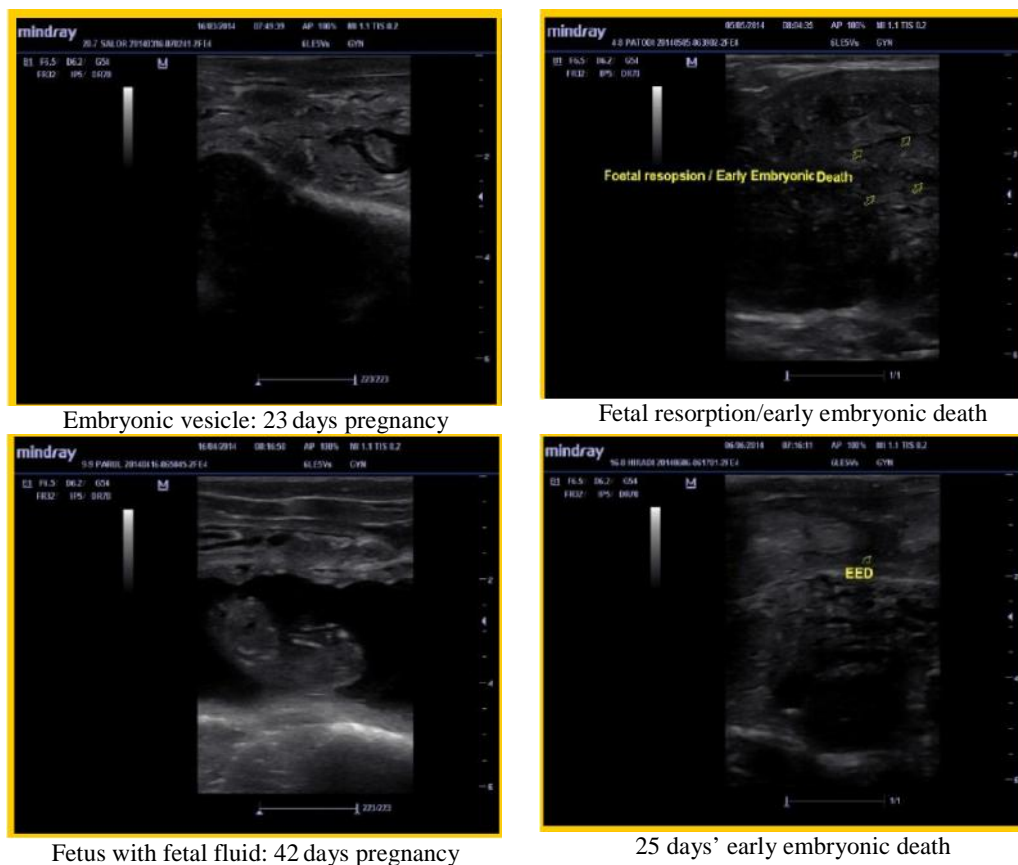


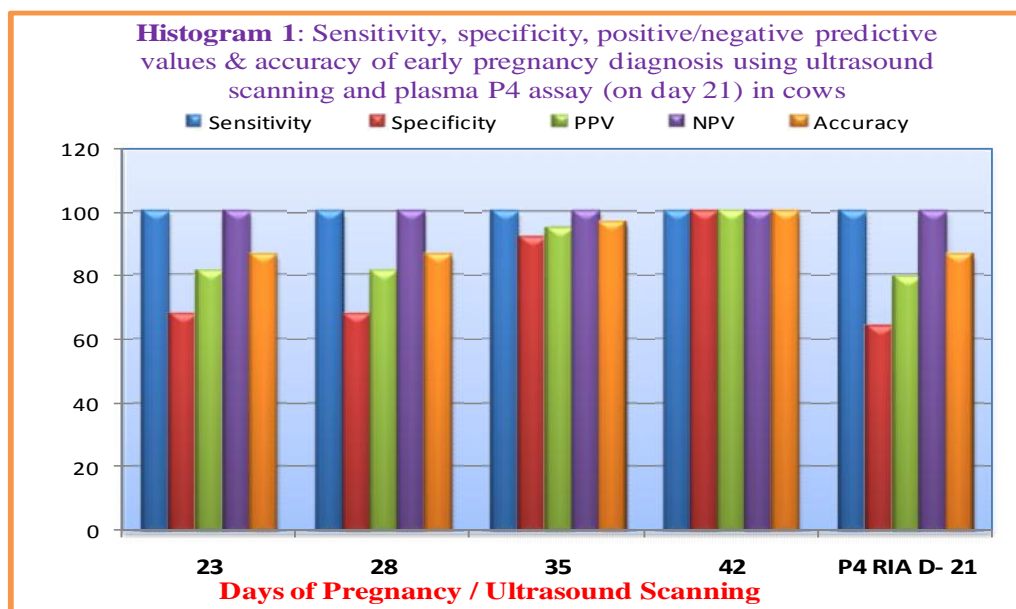
FIGURE 1: Ultrasonograms of early pregnancy and early embryonic mortality in cows

The results of the study showed that, although the sensitivity for early pregnancy was cent per cent on all the 4 days of ultrasound scanning, the specificity was lower on day 23 and 28 (68.00 % each) as compared to day 35 (92.00 %) and 42 (100%). On day 23 and 28, 8 animals were incorrectly diagnosed pregnant, while on day 35 and 42, only two and no animals were wrongly diagnosed pregnant. However, the progesterone assay revealed 9 animals being diagnosed incorrectly pregnant. The

sensitivity and negative predictive values were cent per cent on all days by both the methods, but specificity and positive predictive values were lower for pregnancy diagnosis using progesterone assay (64.00 % and 79.55 %) as compared to ultrasound scanning results on all 4 days (Table 1). Similarly, the accuracy was comparatively higher with ultrasound scanning than the P4 assay (86.67-100 % vs 86.44 %).

TABLE 1: Sensitivity, specificity, predictive values and diagnostic accuracy of early pregnancy detection by ultrasound scanning and plasma progesterone assay in 60 cows in relation to confirmation per rectum 60 days post-AI

Diagnostic results / Predictive values	Ultrasound scanning				Plasma P ₄ Day
	Day 23	Day 28	Day 35	Day 42	21
Number of cows examined	60	60	60	60	60
Diagnosis pregnant correct (a)	35	35	35	35	35
Diagnosis pregnant incorrect (b)	8	8	2	0	9
Diagnosis non-pregnant correct (c)	17	17	23	25	16
Diagnosis non-pregnant incorrect (d)	0	0	0	0	0
Sensitivity (%) = $100 \times a / (a + d)$	100	100	100	100	100
Specificity (%) = $100 \times c / (c + b)$	68.00	68.00	92.00	100	64.00
Positive predictive value (%) = $100 \times a / (a + b)$	81.41	81.41	94.56	100	79.55
Negative predictive value (%) = $100 \times c / (c + d)$	100	100	100	100	100
Overall diagnostic accuracy (%) = $100 \times (a+c)/(a+b+c+d)$	86.67	86.67	96.67	100	86.44



Based on plasma progesterone profile on day 21 post-AI in 60 cows, it was found that 35 cows were correctly diagnosed as pregnant (P_4 , 6.48 ± 0.38 ng/ml) and 16 cows as non-pregnant (P_4 , 0.45 ± 0.13 ng/ml). However, 9 animals were incorrectly diagnosed as pregnant (P_4 , 4.14 ± 0.12 ng/ml) and no animal was incorrectly diagnosed as non-pregnant as compared to the results of pregnancy diagnosis on day 60 by rectal palpation. Out of 9 cows, which were incorrectly diagnosed pregnant on the basis of plasma P_4 profile on day 21 post-AI, 6 were found pregnant on day 23 and 28, but only three were found pregnant on day 35 by ultrasonography indicating early embryonic mortality in three animals (3/35; 8.57%) between day 28 and 35 post-breeding. The technique of ultrasound scanning facilitated the diagnosis of all non-pregnant animals as early as on day 23 post-service. This is an advantage over the technique of rectal palpation for pregnancy diagnosis where it is not possible to get 100 percent reliable result so early in non-pregnancy.

The sensitivity, specificity and accuracy are direct measures of the efficacy of technique and do not change with variation in fertility in the herd. However, the positive predictive value of the test is dependent not only on sensitivity and specificity, but also on the prevalence of condition being tested for. In other words, the reliability of

test is directly proportional to the fertility status of the herd, and hence is of importance to the breeders (Chaffaux *et al.*, 1986; Pieterse *et al.*, 1990). Both the methods of pregnancy diagnosis used in present study, *i.e.* ultrasonography and P_4 profile, at an early stage were fairly accurate with cent per cent predictive values for non-pregnancy.

The results of study showed that transrectal ultrasound scanning of cows on days 23, 28, 35 post-service was less accurate than on day 42. Similar observations have been reported earlier by some workers in cows (Pieterse *et al.*, 1990). However, Bonato *et al.* (1990) and Boyd *et al.* (1990) reported higher accuracy around days 22-26 (92%) and on day 20 (100%), respectively. Patel *et al.* (2005) could detect pregnancy in repeat breeding HF cows as early as on day 23 in 12 out of 24 animals. The absence of embryonic vesicle and its fluid are reliable signs of non-pregnancy (Pieterse *et al.*, 1990). It is, in fact, the non-pregnant animal that must be identified early in order to reduce the calving interval. However, Szenci *et al.* (1998) reported 16.66 per cent cases of false negative diagnosis in cows (5/30) under field conditions when ultrasound scanning was performed between days 27 and 31 post-service. The inability to detect pregnancy was attributed to the location of uterus being far cranial to pelvic inlet and

with transducer of 7.5 MHz frequencies most part of the uterus probably could not be visualized as transducer of higher frequency has limited penetration ability of few centimeters only. In present study, the uterus was located well and was visualized through all the sides with transducer of 6.5 MHz frequencies in all animals. Thus, the chances of missing the embryonic vesicle were negligible.

The specificity, positive predictive value and diagnostic accuracy were comparatively higher on day 35 and 42 post-service, indicating that day 35-42 is the earliest possible time when pregnancy diagnosis should be attempted using ultrasound for maximum accuracy and specificity in zebu cattle. The present findings are consistent with earlier reports in cows (Bonato *et al.*, 1990; Pieterse *et al.*, 1990; Muller *et al.*, 1999; Patel *et al.*, 2005; Awasthi *et al.*, 2011; Bhoraniya *et al.*, 2011). Therefore, ultrasound scanning may be used for early detection of pregnancy on day 35 with positive predictive value over 94.59 percent, and the negative predictive value as well as accuracy of 100%. In the present study, the plasma progesterone concentration ranged from 3.93 to 7.68 ng/ml with an average of 6.48 ± 0.38 ng/ml in pregnant animals on day 21, which approximated well with earlier reports (Patel *et al.*, 2005; Bhoraniya *et al.*, 2011). The positive predictive value and negative predictive value of early pregnancy diagnosis with plasma progesterone was recorded as 79.55 and 100.00 percent, respectively, in present study, which corroborated with the findings of Patel *et al.* (2005). Contrary to this, Chung and Kim (1980) found that accuracy of pregnancy diagnosis based on progesterone profile on day 24 or 25 was 91 % for positive and 88% for negative results. Holness *et al.* (1977) reported 10 per cent embryonic mortality between 26 to 81 days after insemination in cows based on P₄ values on day 20 and later on rectal palpation findings. In our study, three animals with plasma progesterone level of 3.93 ng/ml were found pregnant through ultrasound scanning at all 3 occasions from 23 to 35 days post-service, and luteolysis probably had just begun after ultrasound scanning on day 35, thus allowing embryonic vesicle to be observed through ultrasound scanning during this period. There might be gradual decline in plasma progesterone concentration resulting in loss of embryo between days 35 and 60 prior to rectal palpation. This speculation was consistent with the report of Chaffaux *et al.* (1986). Nation *et al.* (2003) opined that one should not have any confusion between ultrasound images of embryonic vesicle and fluid due to uterine infection, and that the technique is less traumatic for animal and more efficient for operator. Although approximately 4 to 6 % of embryos and/or fetuses might be lost between the early stages and 13-week of pregnancy, this method has considerable merit for rapid identification of animals that are non-pregnant to first service and has not returned to estrus within 24 to 30 days after service.

CONCLUSIONS

The technique of ultrasound scanning facilitated the diagnosis of all non-pregnant cows as early as on day 23 post-service. This is an advantage over the technique of rectal palpation for pregnancy diagnosis, where it is not

possible to get 100 percent reliable result so early in non-pregnancy. Ultrasound examinations between day 28 and 35 post-breeding helped confirm early embryonic mortality in 8.57 percent cows. The specificity, positive predictive value and diagnostic accuracy were comparatively higher on days 35 and 42 post-service, indicating that day 35-42 is the ideal earliest possible time when pregnancy diagnosis should be attempted using ultrasound for maximum accuracy and specificity in cattle.

ACKNOWLEDGEMENT

We thank the Dean of the Faculty and the Scientist-in-Charge of Livestock Research Station of the University for the facilities provided and permission granted to take up this work on their animals.

REFERENCES

- Arthur, G.H., Noakes, D.E. and Pearson, H. (1989) *Veterinary Reproduction and Obstetrics*. 7th Edn., ELBS Publication, pp. 417.
- Awasthi, M.K., Khare, A., Kavani, F.S., Siddiquee, G.M. and Dhami, A.J. (2011) Early pregnancy diagnosis in water buffaloes using trans-rectal ultrasonography. *Indian J. Anim. Reprod.*, **32**(1): 47-79.
- Badtram, G.A., Gaines, J.D., Thomas, C.B. and Bosu, W. T.K. (1991) Factors influencing the accuracy of early pregnancy detection in cattle by real-time ultrasound scanning of the uterus. *Theriogenology*, **35**: 1153-67.
- Bhoraniya, H.L., Dhami, A.J., Naikoo, M. & Divekar, B.S. (2011) Early pregnancy diagnosis through transrectal ultrasonography and plasma progesterone assay in Kankrej cows. *Indian J. Anim. Reprod.*, **32**(2): 23-26.
- Bonato, O., Fiocca, A., Pigato, M. and Scorzato, I. (1990) Early diagnosis of pregnancy by ecography in cattle. *Praxis Veterinaria (Milano)*, **11**(2): 18-20 (c.f. *Vet. Bull.*, **61**: 3132).
- Boyd, J.S., Omran, S.N. & Ayliffe, T.R. (1990) Evaluation of real-time B-mode ultrasound scanning for detecting early pregnancy in cows. *Vet. Rec.*, **127**: 350-352.
- Chaffaux, S., Reddy, G.N.S., Valon, F. and Thibier, M. (1986) Trasrectal real-time ultrasound scanning for diagnosing pregnancy and for monitoring embryonic mortality in dairy cattle. *Anim. Reprod. Sci.*, **10**(3): 193-200.
- Chung, Y.C. & Kim, C.K. (1980) Study on the early diagnosis of pregnancy in cows. *9th Int. Congr. Anim. Reprod. and AI, Madrid, Spain*, 16-20 June, Abstr. 119.
- Holness, D.H., Ellison, J.A., Sprowson, G.W., Carvalho, A. de. & De-Carvalho, A. (1977) Aspects of fertility in Friesland dairy cows with particular reference to the concentration of progesterone in peripheral plasma. *Rhodesian J. Agril. Res.*, **15** (2): 109-117.

- Muller, K., Drillich, M., Tenhagen, B.A., Heuwieser, W. (1999) Sensitivity and specificity of pregnancy examination by means of ultrasound between day 20 and 34 after artificial insemination in dairy cattle. *Praktische Tierarzt.*, **80** (12): 1095-1100.
- Nation, D.P., Malmo, J., Davis, G.M. & Macmillan, K.L. (2003) Accuracy of bovine pregnancy detection using transrectal ultrasonography at 28 to 35 days after insemination. *Aust. Vet. J.*, **81**: 63-65.
- Patel, J.A., Kavani, F.S., Derashri, H.J. & Sarvaiya, N.P. (2005) Use of ultrasonography in detection of early pregnancy and embryonic mortality in Holstein Friesian cow. *Indian J. Dairy Sci.*, **58**(5): 352-355.
- Pierson, R.A. and Ginther, O.J. (1984) Ultrasonography for detection of pregnancy and study of embryonic development in heifers. *Theriogenology*, **22**(2): 225-233
- Pieterse, M.C., Szenci, O., Willemse, A.H., Bajcsy, C.S.A., Dieleman, S.J. and Taverne, M.A.M. (1990) Early pregnancy diagnosis in cattle by means of linear array real-time ultrasound scanning of uterus and a qualitative and quantitative milk progesterone test. *Theriogenology*, **33**: 697-707.
- Szenci, O., Varga, J. and Bajcsy, A.C. (1998) Role of early pregnancy diagnosis by means of ultrasonography in improving reproductive efficiency in a dairy herd: a retrospective study. *Bovine Practitioner*, **32**(2): 67-69.
- Totey, S.M., Singh, G., Taneja, M. & Talwar, G.P. (1991) Ultrasonography for detection of early pregnancy following embryo transfer in unknown breed of *Bos indicus* cows. *Theriogenology*, **35**(3): 487-497.