



REVERSIBLE ANTIFERTILITY EFFECT OF *CYAMPOSIS PSORALIOIDES* IN MALE SWISS ALBINO MICE

Thejashwini, M.S., Krishna Ram, H. & Shivabasavaiah

Department of Studies in Zoology, University of Mysore, Manasagangotri, Mysore 570 006, Karnataka, India.

ABSTRACT

Present study was undertaken to evaluate the reversible antifertility effect of *Cyamposis psoralioides* (Guar gum) pod on male Swiss albino mice. The mice were orally administered the ethanol crude extract (200mg/Kg body weight and 400mg/Kg body weight) for 40 days. Effect of the treatment on reproductive organs and fertility was investigated and the testosterone level was determined by RIA. The results revealed that the low dose of 200mg/Kg body weight treatment caused 50% reduction in the fertility of male mice, whereas in high dose 400mg/Kg body weight caused 100% reduction in the fertility of male mice. The treatment caused reduction in the number of spermatozoa in cauda epididymis ($P<0.001$, $P<0.001$). The weight of reproductive organs viz., testis ($P<0.001$, $P<0.001$), epididymis ($P<0.01$, $P<0.01$), seminal vesicle ($P<0.05$, $P<0.001$), vas deferens ($P<0.001$) and ventral prostate ($P<0.001$, $P<0.001$) decreased significantly. Serum testosterone level reduced significantly ($P<0.001$, $P<0.001$) when compared to the control group. Histometry showed reduction in the diameter of seminiferous tubules ($P<0.001$, $P<0.001$) and diameter of the Leydig cells ($P<0.001$, $P<0.001$). Biochemical parameters of testis like total protein ($P<0.05$, $P<0.05$), Cholesterol ($P<0.05$, $P<0.05$), ascorbic acid ($P<0.01$, $P<0.05$) and glycogen ($P<0.01$, $P<0.001$) showed statistical significant differences when compared to the control group. Both the groups of animals were maintained for 30 days without any treatment to check the reversibility. All the animals after the recovery period showed normal fertility rate. From this we can conclude that guar gum can be used as a potent antifertility agent.

KEY WORDS: *Cyamposis psoralioides*, reversibility of antifertility, antispermatogenesis, male fertility, contraception.

INTRODUCTION

One of the important concerns today's is the problem of over population. If the population increase is not controlled or checked, it will lead to several problems (Sailani and Moeini, 2008). The solution to this predicament is population control. India opted for family planning to control the increase in population (Sarkar, 1996). Various methods of contraception were used for fertility control. There are a variety of methods available and are in use for female contraception (Bajaj, 1999). In contrast, except for the barrier method and vasectomy, there are no methods available for male contraception. Thus, there is need to develop multiple male contraceptive methods. The risk obtained by the drugs has triggered the need to develop newer molecules from medicinal plants. Hence there is need to search suitable products from indigenous medicinal plants, that could be effectively used (Absar *et al.*, 2006). Many local plants have been identified and tested for their antifertility effect in male rats and mice (Sharma *et al.*, 1999).

Cyamposis psoralioides commonly called Guar gum is a coarse, summer growing, leguminous annual that is propably native to India and is widely distributed across Africa and Asia. *Cyamposis psoralioides* is commonly called as Guar pea. It has favorable long term effects on glycemic control and lipid concentration (Grooph *et al.*, 1993). Partially hydrolyzed guar gum helps in recovery of children from diarrhea (Alam *et al.*, 2005) and has the

medicinal property to cure Irritable Bowel Syndrome (IBS) (Giannini *et al.*, 2009). Guar gum potentially used as

colon-specific drug carrier (Kabir *et al.*, 1998). From the above said medicinal property we worked on Swiss albino mice to see the reversible antifertility effect in male.

MATERIAL AND METHODS

Extraction procedure

Cyamposis psoralioides were purchased from the local market. The fresh pod were ground in a grinder and mixed with 90% of alcohol (500ml) allowed for 12 hours in magnetic stirrer and then subjected to soxhalation. The 100 gram of pod yields 1gm of extract. The yield of thick viscous was found to be soluble in water. The required doses therefore were freshly prepared by dissolving it in the required quantity of water.

Animals (experimental procedure)

Swiss albino mice of 12-14 weeks weighing 30 g were used in the investigations. Mice were maintained under hygienic conditions in well ventilated room and were fed with pelleted food; drinking water was available ad libitum. The animals were randomly categorized into three groups of ten animals each and treated as follows.

Group 1: Control mice that received 0.1 ml of double distilled water/ kg b.w for 40 days.

Group 2: Male mice treated with the pod extract of 200mg/Kg b.w for 40 days.

Group 3: Male mice treated with the pod extract of 400mg/Kg b.w for 40 days.

Group 4: Male mice treated with the pod extract of 200mg/Kg b.w for 40 days and allowed without any treatment for 30 days to check the reversibility.

Group 5: Male mice treated with the pod extract of 400mg/Kg b.w for 40 days and allowed without any treatment for 30 days to check the reversibility.

Body and reproductive organs weight

Body weight of control and experimental animals were weighed during experiment. After 24 hrs of the last dose the mice were killed by cervical dislocation. Testes, epididymis, seminal vesicle, ventral prostate were dissected out, cleared of fat and connective tissue and weighed. From one side of the body part reproductive organs were fixed in Bouin's fixative for the microtome and other side of the body part reproductive organs (testis, epididymis and vas deferens) was kept in a -20°C for biochemical studies. During the autopsy the blood was drawn from the heart and the blood was used for testosterone hormonal assay. 20 slides from the testis were taken for the micrometry study (diameter of seminiferous tubule and Leydig cell diameter).

Gravimetry

The weights of the dissected organs were calculated for 100g body weight of animal by using the following formula

$$\text{Weight of organ} = \frac{\text{Wet weight of organ}}{\text{Body weight}} \times 100 = \text{g/1000g b wt.}$$

Fertility test

The mating exposure tests on control and treated groups were performed on 20th day. The control and treated male mice cohabited with proestrous females in ratio of 1:2. In the next morning vaginal plug and the presence of sperm in the vaginal smear were checked for positive mating. The mated females were separated and allowed to complete the gestation (WHO MB- 50).

Sperm count and differential count of sperm

Sperm analysis was performed on samples derived from the caudal epididymis. Briefly, caudal epididymis were sliced with a sharp razor blade, suspended in 1ml of phosphate buffer saline (PBS) in a Petri dish and gently shaken for 15 minutes. The suspension was passed through a nylon mesh to separate the tissue from the sperm. Sperm counts were made in a improved Neubauers chamber. To check the abnormalities of sperm head, the sperm suspension was stained with 2% of the eosin stain and the above said suspension drop was taken on a clean slide and made a thin smear on that with the help of another slide and allowed for drying. This slide was examined under microscope (400 X) (Vega *et al.*, 1988).

Hormonal assay

0.5 ml of serum was taken to study the testosterone level in blood; this was done by Radio Immuno Assay method (RIA) (Wilke and Utley, 1978).

Histology and Histometry

The portion of testis was fixed in Bouins fluid, dehydrated in ascending grades of alcohol, Embedded in paraffin wax and sectioned at 5µ and stained with haematoxyline and eosin. The micrometric measurements such as diameter of seminiferous tubule and diameter of the Leydig cell were measured from randomly selected twenty round sections from each group. The diameter of the Leydig cell was

done under 1000X and seminiferous tubule diameter was done under 400X.

Biochemical parameters

Protein estimation was done according to Lowry *et al.*, (1951). Glycogen estimation was done according to Carrol, 1956. Cholesterol estimation was done according to Peters and Vanslyke (1946). Ascorbic acid estimation was done according to Roe and Kuether (1943).

Statistical analysis

Data obtained were analyzed statistically by Student's t test.

RESULTS

Body and Organ weight

Body weights did not change significantly in ethanolic pod extract groups when compared to the control group (Table 1). In both the treated groups the weight of the testis and other reproductive organs decreased significantly when compared to the control group (Table 2). Group 4 and 5 animals did not show any statistically significant difference when compared to the control. From the present results it is evident that the Guar gum treatment did not cause significant reduction in the animal body weight when compared to control, which shows that there is no toxic side effect of the plant extract.

Fertility test

Daily oral administration of 400 mg/Kg b.w. crude ethanolic extract of *Cyamopsis psoralioides* pod for 40 days caused 100% inhibition of fertility, whereas in case of group 2 animals the treatment caused 50% inhibition of fertility, when compared to the control (Table 3). Group 4 and 5 animals were able to reproduce after withdrawal of the treatment.

Hormonal assay

In both groups 2 and 3 there is a significant reduction ($P<0.001$) in testosterone level when compared to the control group (Table 4). There is a significant reduction ($P<0.001$) of testosterone level in high dose group when compared to control. Group 4 and 5 animals did not show any statistically significant difference when compared to the control.

Sperm count and Abnormalities

In addition to inhibition and fertility to the extent of 100% in group 3 and 50% in group 2 animals, statistically significant reduction in the caudal epididymal sperm counts [group 2 ($P<0.001$) group 3 ($P<0.001$)] also occurred. In group 3 significant increase in the sperm abnormalities like Amorphous head ($P<0.001$), Hammer head ($P<0.001$), Pin head (Table 5) were seen. Group 4 and 5 animals did not show any statistically significant difference when compared to the control.

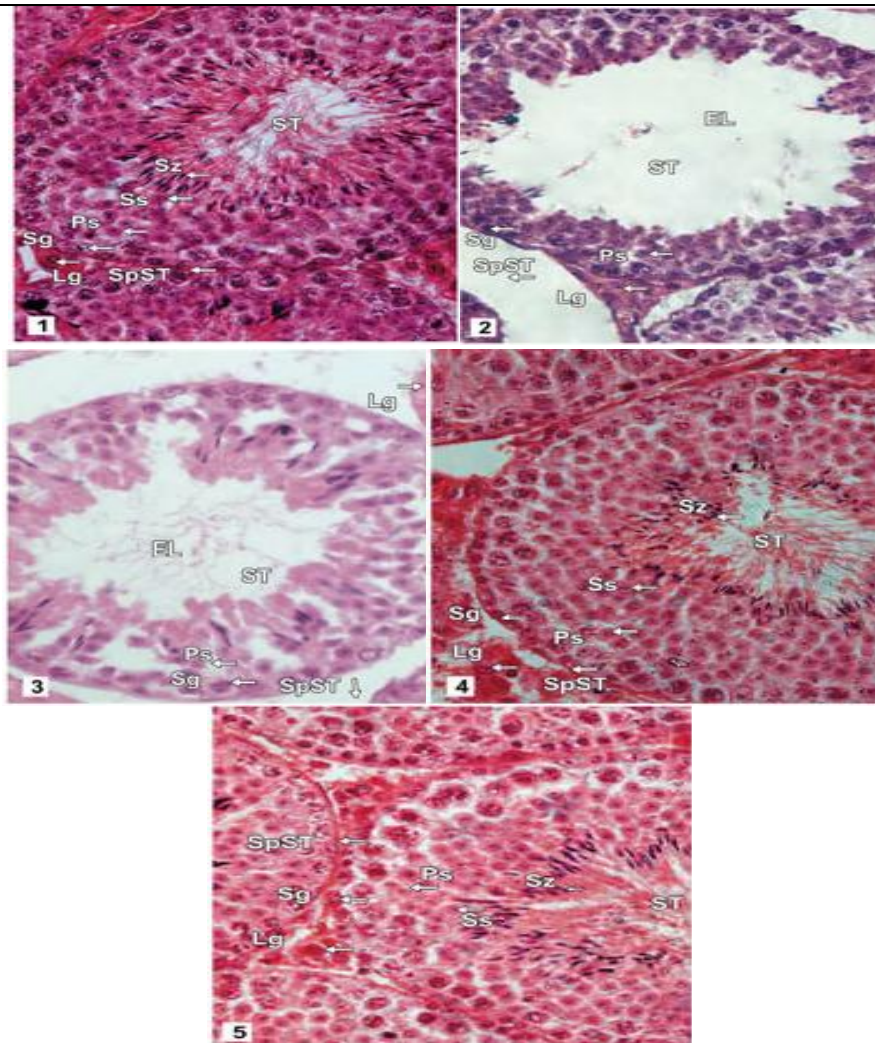
Histology and Histometry

In both groups 2 and 3 there is a significant reduction in diameter of the seminiferous tubule group 2 ($P<0.001$) and group 3 ($P<0.001$) and Leydig cell diameter [group 2 ($P<0.001$) and group 3 ($P<0.001$)]. The space between the tubules was found to be increased in treated group as compared to that of control because of shrinkage of the seminiferous tubule (Fig. 1) and (Fig.2). But normal histology is seen in group 4 and 5.

TABLE 1: Effect of *Cyamopsis psoralioides* extract (40 days) on body weight of male Swiss Albino Mice.

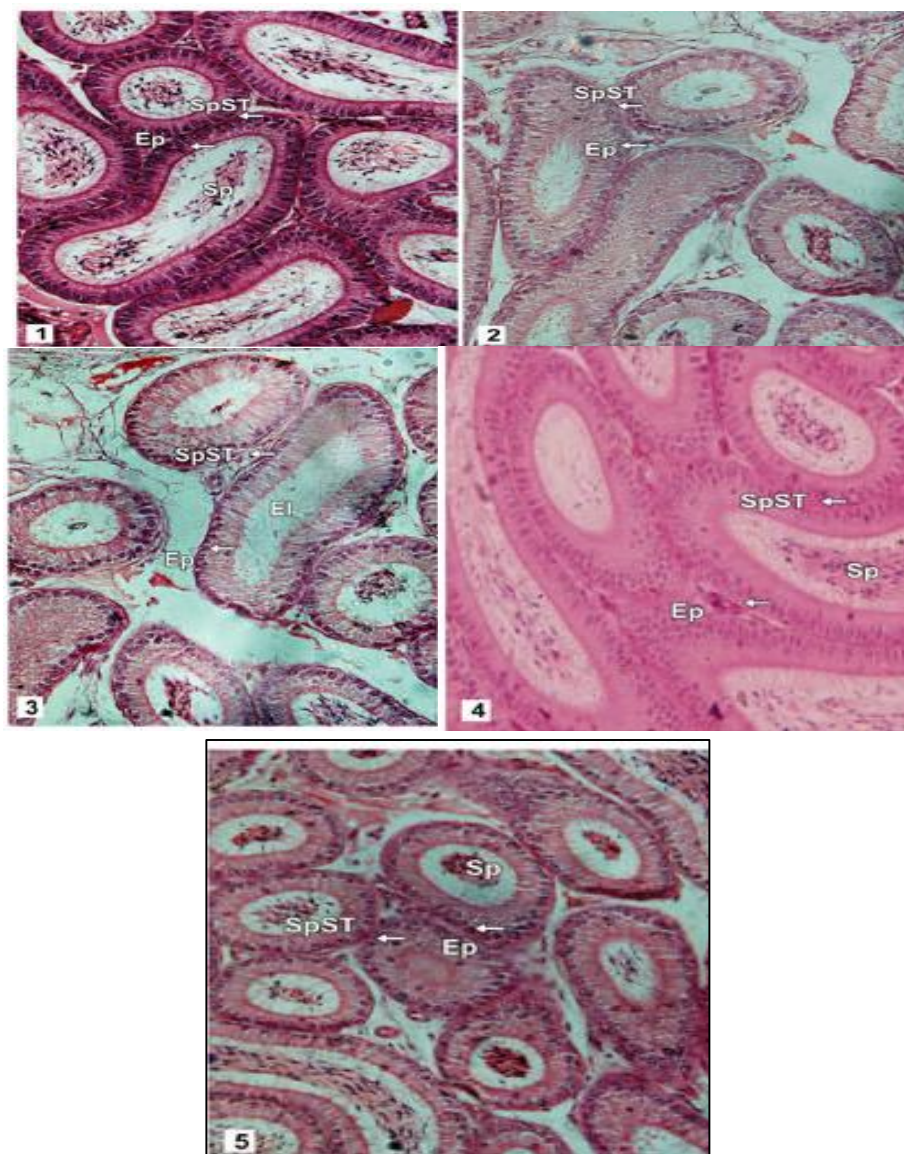
FIGURE 1

Treatment	Initial body weight (g)	I week	II week	III week	IV week	Final body weight V week	VI week	VII week
Group I	34.8±0.79	36.3±1.23	37.5±0.87	38±1.96	39.2±0.82	41±1.32	-	-
Group II	33.35±0.55	34±0.59	35±0.77	37±0.86	39.2±1.03	40±0.73	-	-
Group III	34.8±0.53	37.05±0.62	37.65±0.62	38.35±0.63	38.60±0.70	40.80±0.75	-	-
Group IV	34.4±0.68	35±0.53	37±0.90	37.65±0.62	38.86±0.64	39.8±0.85	40.8±0.75	41±1.05
Group V	34.6±0.47	35.1±0.74	37±0.85	38±0.73	39±0.89	40±0.47	41.3±2.22	43.05±0.63



Transverse Section of testis of male Swiss albino mice **Fig 1:** C.S of Control II mice testis (400 X). Enlarged seminiferous tubules with intensive spermatogenic activity and sperm bundles showing different stages of spermatogenic cells i.e **Sg**, **Ps**, **Ss**, **ST**, and **Lg**. **Fig 2:** C.S of Group III mice testis (400 X). The regressed condition of seminiferous tubule with decreased spermatogenic activity with few **Sg**, **Ps** and empty lumen in the seminiferous tubule. The space between the tubule has become widen. **Fig 3:** C.S of Group IV mice testis (400 X). The regressed condition of seminiferous tubule with decreased spermatogenic activity with few **Sg**, **Ps** and empty lumen in the seminiferous tubule. The space between the tubule has become widen. **Fig 4:** C.S of Group VI mice testis (400 X), There is no much difference when compared to the control testis, it shows the intensive spermatogenic activity and sperm bundles showing different stages of spermatogenic cells i.e **Sg**, **Ps**, **Ss**, **ST**, and **Lg**. **Fig 5:** C.S of Group VII mice testis (400 X). There is no much difference when compared to the control testis, it shows the intensive spermatogenic activity and sperm bundles showing different stages of spermatogenic cells i.e **Sg**, **Ps**, **Ss**, **ST**, and **Lg**. **ST** ; Seminiferous tubule, **Sg**; Spermatogonia , **Ps**; Primary spermatocytes, **Ss**; Secondary spermatocyte, **Sz**; Spermatozoa, **Lg**; Leydig cell, **Sp ST** ; Space between the tubule, **EL**; Empty lumen.

FIGURE 2



Transverse Section of Epididymis of male Swiss albino mice, Fig 1: C.S of Control II mice Epididymis (100 X). The tubules are compactly arranged, epithelial cells are seen with dense spermatozoa in the tubules. **Fig 2:** C.S of Group III mice Epididymis (100 X). The space between the tubules has become wider; the concentration of sperm in the tubule has become low. The epithelial cells remain unchanged. **Fig 3:** C.S of Group IV mice Epididymis (100 X). The space between the tubules has become wider; the concentration of sperm in the tubule is low. The epithelial cells remain unchanged. **Fig 4:** C.S of Group VI mice Epididymis (100 X). There is not much difference seen when compared to the control mice. **Fig 5:** C.S of Group VII mice Epididymis (100 X). There is not much difference seen when compared to the control mice. **Sp ST**; Space between the tubules, **Ep**: Epithelial cell, **sp**: Sperm

TABLE 2: Effect of *Cyamopsis psoralioides* extract on the body weight (40 days) and reproductive organs weight (mg) in the male Swiss Albino mice.

Treatment	organs weight/ (mg/100g b wt)				
	Testis	Epididymis	Vas deferens	Seminal vesicle	Ventral prostate
Group I	0.791±0.008	0.263±0.005	0.115±0.001	0.586±0.10	0.227±0.001
Group II	0.719±0.003***	0.238±0.003**	0.105±0.005	0.556±0.004*	0.215±0.004***
Group III	0.659±0.003***	0.231±0.003**	0.085±0.001**	0.508±0.004***	0.196±0.002***
Group IV	0.787±0.01	0.252±0.010	0.112±0.004	0.582±0.01	0.251±0.267
Group V	0.776±0.008	0.248±0.007	0.105±0.002	0.579±0.01	0.222±0.003

TABLE 3: Effect of *Cyamposis psoralioides* extract (40 days) on Fertility of male Swiss Albino mice.

Treatment	Fertility test			
	No of mated male/ females	No of pregnant females	No of litters born	Percentage of fertility
Group I	2/4	4	36	100%
Group II	2/4	4	18	50%
Group III	2/4	0	0	0%
Group IV	2/4	4	36	100%
Group V	2/4	0	36	100%

TABLE 4: Effect of *Cyamposis psoralioides* extract (40 days) on Testicular histometry, Sperm count and testosterone level of male Swiss Albino mice

Treatment	Histometry, Sperm count and Testosterone level			
	Diameter of Seminiferous tubule (100X)	Diameter of Leydig cell (1000X)	Sperm count (Millions)	Testosterone (ng/Dl)
Group I	48.46±0.55	5.96±0.05	5.1±0.13	540±2.9
Group II	34.29±0.16***	4.13±0.006***	3.6±0.09***	373±3.1***
Group III	25.19±0.37***	3.94±0.04***	1.1±0.02***	258±7.81***
Group IV	47.30±0.48	5.1±0.19	4.78±0.15	534±4.26
Group V	48.2±0.30	5.4±0.21	4.85±0.082	533±3.35

TABLE 5: Effect of *Cyamposis psoralioides* extract (40 days) on sperm abnormalities of the male Swiss Albino mice.

Treatment	Sperm Abnormalities				
	Normal head	Amorphous head	Hammer head	Banana head	Pin head
Group I	94.4±0.52	3.1±0.54	1±0.33	0.8±0.51	0.9±0.37
Group II	92.1±0.48***	2.2±0.56	2.2±0.69	1±0.29	2.5±0.56*
Group III	82.6±0.06***	6.2±.53***	5.9±0.73***	1±0.29	4.6±0.79***
Group IV	92.4±0.45	2.8±0.13	2.4±0.16	1.6±0.16	0.8±0.24
Group V	92.2±0.57	5.4±1.98	2.0±0.21	1.6±0.16	0.8±0.24

BIOCHEMICAL STUDIES

Protein

In group 2 animals the protein value in testis ($P<0.05$) and vas deferens ($P<0.05$) showed statistically significant difference when compared to the control group, while epididymis did not show any difference. Whereas in group

3 animals the protein value showed statistically significant difference (testis $P<0.05$, epididymis $P<0.05$ and vas deferens $P<0.01$). In group 4 and 5 animals after the

recovery period, normal protein value was recorded (Table 6).

Glycogen

In group 2 animals the glycogen value in testis ($P<0.01$) showed statistically significant difference when compared to the control group. While epididymis and vas deferens did not show any statistically significant difference. Whereas in group 3 animals the glycogen value showed statistically significant difference (testis $P<0.001$, epididymis $P<0.001$ and vas deferens $P<0.05$). In group 4 and 5 animals after the recovery period, normal glycogen value was recorded (Table 7).

TABLE 6: Effect of *Cyamposis psoralioides* extract (40 days) on Protein level in male Swiss Albino mice

Treatment	Protein level $\mu\text{g}/\text{mg}$		
	Testis	Epididymis	Vas deferens
Group I	14.38±0.79	32.37±0.59	32.94±1.11
Group II	12.10±0.58*	31.38±0.59	29.9±0.85*
Group III	11.19±0.74*	30.50±0.46*	28.6±0.52**
Group IV	13.32±0.22	31.18±0.61	31.75±1.06
Group V	12.78±0.41	31.40±0.52	30.11±0.99

TABLE 7: Effect of *Cyamposis psoralioides* extract (40 days) on Glycogen level in male Swiss Albino mice.

Treatment	Glycogen level $\mu\text{g}/\text{mg}$
-----------	--

	Testis	Epididymis	Vas deferens
Group I	2.50±0.12	5.78±0.18	14.45±0.39
Group II	1.77±0.13**	5.12±0.30	13.74±0.69
Group III	0.92±0.04***	3.51±0.37***	13.01±0.61*
Group IV	1.84±0.15	4.94±0.32	14.18±0.32
Group V	1.82±0.087	5.46±0.15	13.98±0.23

Cholesterol

In group 2 animals the cholesterol value in testis ($P<0.05$) showed statistically significant difference when compared to the control group. While epididymis did not show any statistically significant difference. In group 3 animals the cholesterol value showed statistically significant difference (testis $P<0.01$). While epididymis did not show any statistically significant difference. In group 4 and 5 animals after the recovery period, normal glycogen value was recorded (Table 8).

Total ascorbic acid (TAA)

In group 2 animals the (TAA) value in testis ($P<0.01$) and epididymis ($P<0.01$) showed statistically significant difference when compared to the control group. While vas deferens did not show any statistically significant difference. In group 3 animals the (TAA) value showed statistically significant difference (testis $P<0.05$, epididymis $P<0.001$ and vas deferens $P<0.001$). In group 4 and 5 animals after the recovery period, normal TAA value was recorded (Table 9).

TABLE 8: Effect of *Cyamposis psoralioides* extract (40 days) on Cholesterol level in male Swiss Albino mice.

Treatment	Cholesterol level $\mu\text{g}/\text{mg}$	
	Testis	Epididymis
Group I	4.74±0.40	5.28±0.73
Group II	3.29±0.29*	4.4±0.73
Group III	3.06±0.27**	2.66±0.35
Group IV	3.89±0.40	4.48±0.73
Group V	4.46±0.34	3.65±0.75

TABLE 9: Effect of *Cyamposis psoralioides* extract (40 days) on Ascorbic acid level in male Swiss Albino mice

Treatment	Ascorbic acid level $\mu\text{g}/\text{mg}$		
	Testis	Epididymis	Vas deferens
Group I	0.25±0.01	0.33±0.01	0.28±0.01
Group II	0.23±0.01**	0.28±0.01**	0.25±0.01
Group III	0.19±0.007*	0.25±0.01***	0.19±0.01***
Group IV	0.23±0.01	0.29±0.01	0.26±0.007
Group V	0.23±0.01	0.30±0.01	0.27±0.004

DISCUSSION

The search for plants for male fertility regulation is comparatively smaller as it is directed towards the inhibition of millions of sperms produced daily as against one ovum released every month in females. However, attention has been given in this modern era and attempts have been made to bring out safe, effective plant preparations as ideal contraceptives for males (Zeherea *et al.*, 1998). In the present investigation, it was observed that the Guar pea treatment did not cause significant reduction in the animal body weight when compared to control. This shows the absence of toxic side effect of the plant in the animals tested. The same result has been found in the administration of *Alstonia scholaris* bark extract (Gupta *et al.*, 2002), *Strychnos potatorum* seed extract (Gupta *et al.*, 2006), *Tuniperus phoenicea* (Shkukani *et al.*, 2007) to male rats and *Achillea millefolium* flower extract (Montanari *et al.*, 1998) to male mice. In this study the significant reduction of testis

weight were seen, which is known to be mostly related to number of spermatids and spermatozoa present in the tissue. (Gupta *et al.*, 2005). The significant reduction in the weight of reproductive organs indirectly supports the reduced availability of androgen (Zeherea *et al.*, 1998). Androgen deprivation not only suppresses spermatogenesis, leading to low sperm concentration, but also alters the epididymal milieu which renders it hostile for maturation and survival of the spermatozoa (Setty, 1979 & Rao, 1988). Testosterone, an important androgen, plays a pivotal role in maturation, spermatogenesis and the maintenance of accessory sex organs (Keel & Abney, 1981). The structural and functional integrity of reproductive tissues depends on the circulating androgen (Chinoy *et al.*, 1982) and therefore, any small change in testosterone content may result in reductions in the weights of the reproductive organs. The significant reduction of testosterone level in blood indicates the reduction of androgen level in high dose treated animal. The ability of the extract fed mice to mate might have been possible because of low androgen concentration (Sondersten, 1979) or owing to circulating plasma testosterone, which was sufficient for normal mating behavior, but insufficient for the maintenance of

fertilizing ability of the epididymal spermatozoa (Bhasin *et al.*, 1988). Androgen deprivation not only suppresses spermatogenesis, leading to low sperm concentration, but alters the epididymal milieu also, which renders it hostile for physiological maturation and survival of the spermatozoa (Setty, 1979; Rao and Mathur, 1988; Rao and Shah, 1988).

Histometric and histological studies indicate the effect of ethanolic extract of *Cyamposis psoralioides* pod cause significant reduction in the diameter of seminiferous tubules and Leydig cells in treated animals. The similar result is found in the administration of Brahmi in mice (Singh and Singh, 2008) and *Ocimum sanctum* in rats (Ahmed *et al.*, 2008) have revealed significant regression in the seminiferous tubular diameter, with marked degenerative changes in the tubules. The reduced testicular weights and shrunken seminiferous tubular dimensions indicate wide spread damage (Keel and Abney, 1980). A reduction in the diameter of Leydig cells could be due to a destructive effect of *C.psoralioides*. The same result has been found out by Udoh (Udoh & Kehinde 1999), since these cells from the major endocrine portion of the gonads they produce male androgens including testosterone which is controlled by the anterior pituitary gonadotrophins (Follicle stimulating hormone/ Leutininising hormone/ interstitial cell stimulating hormone, FSH/ LH/ CSH). This disruptive effect could be direct or indirect effect of androgen on the tubules. Since the tubules require a high concentration of androgen for cell maturation and function, the disruption of androgen leads to a lower concentration of androgen and this could cause the histological changes observed in the tubules (Udoh and Kehinde. 1999). Regression of Leydig cells diameter after the treatment suggests the antispermatic activity of *Cyamposis psoralioides* in male mice. Various plants like *Vinca rosea* (Murugavel *et al.*1989), *Solanum xanthocarpum* (Rao. 1988), *Banbusa arundinacea* (Kumari *et al.*, 1989), *Ocimumcsancpum* (Kantak *et al.* 1992) , *Carica papaya* (Lohiya & Goyal 1992) and *Spirulina plantensis* (Murugan *et al.*, 1993) have been reported to posses antifertility activity. Treatment with above said plant materials could reduce sperm count, fertility and viability and increase the amount of abnormal sperm (Ghosesawar *et al.*, 2003). In the same manner treatment with Guar gum decreases the sperm count and increase the abnormality of sperm which leads to decrease in the concentration of sperm in the treated animals. Inadequate concentrations of spermatozoa fail to penetrate the cervical mucus and thus fail to fertilize the ova (Setty 1979 & Rao 1988).

Oral administration of ethanolic extract of *Cyamposis psoralioides* caused statistically significant decrease in protein, glycogen and ascorbic acid levels in testis, epididymis and vas deferens. The cholesterol level has decreased in testis and vas deferens in Group II, III and IV animals. The low levels of testicular protein are usually indicative of inhibition of spermatogenesis (Dixit and Bhargava, 1983). Similar result was reported by Vijaykumar *et al.*, (2004), Chinoy *et al.*, (2005), Chinoy and Mehta (1999).The reduced protein content may also be another reason, as the growth rate of any organ is proportional to its protein content, since evidently FSH

stimulates the development of spermatogonia to spermatocytes and also maintains the spermatogenic process (Connel and Eik-Nes, 1968). The sertoli cells and spermatogonia contain glycogen and provide nourishments to the seminiferous tubular cells and the glycogen content is found to be directly proportional to the steroid hormone levels (Rommerts *et al.*, 1974). A decrease in glycogen content of the testis reduces the energy source for spermatogenic activity. The reduced glycogen level could affect protein synthesis; because of protein synthesis in spermatogenic cells was dependent on glucose (Dixit *et al.*, 1979). In the present study the decreased glycogen content of the testis after the administration of *Cyamposis psoralioides* extract may reduce the energy source for spermatogenic activity, which might have resulted in spermatogenic arrest. Mammalian cells require cholesterol which plays an important role in acting as precursor molecule in the synthesis of steroid hormones (Gupta, 2005) and its level is related to fertility (Eik-Nes and Hall, 1962). Treated animals show significant decrease in the testicular cholesterol level indicating that the metabolism might have undergone alteration. Ascorbic acid prevents free radicals inducing DNA damage in testis (Dawson *et al.*, 1990). It is evident from the present study, *Cyamposis psoralioides* pod extract caused decreased level of ascorbic acid in the testis of male mice, which is in consonance with that of Chatterjee *et al.*, (1994), Chaudhary and Singh (2006) who reported hypo functioning of testis and the degeneration of the germinal epithelium due to vitamin C deficiency.

Clinical assessment of male antifertility agents should include acceptability, safety and efficacy during and after the treatment. Such agents must have reversible antifertility effect. Our present data shows the reversible effect of the treatment. Complete recovery of fertility was observed following the withdrawal of the treatment. In the present work after the recovery period of 30 days all the animals were able to reproduce normally when compared to the control groups. The similar results were found when the administration of *Carica papaya* seed to the rat (Chinoy *et al.*, 1994), *Curcuma longa* to the rat (Mishra and Singh, 2009), *Allamanda cathartica* to the male mice (Singh and Singh, 2008). From the above result we conclude that Guar gum treatment has reversible antifertility effect in male Swiss albino mice.

REFERENCES

- Absar. A., Qureshi., Dhirendra, B, Sanghai., and Padgilwar S.S (2006) Herbal options for Contraceptions: A Review Pharmacology magazine.
- Ahmed, M., Ahmed, R.N., Aladakatti, R.H., and Deepthi, K.R (2008) Reversible histoarchitecture study of testis and cauda epididymis and changes in cauda epididymal epithelial cell types on treatment with benzene extract of *Ocimum sanctum* leaves in albino rats. Oriental Pharm.Exp.Med. 8(2): 111-124.
- Alam, N.H., Meier, R., Sarker, A., Bardhan, P.K., Schnedier H., and Gyr N (2005) Partially hydrolised Guar pea supplemented comminuted chicken diet in persistent

diarrhoea : a randomized controlled trial. Arch Dis Child, 90: 195-199.

Bajaj Rajalakshmi Mand, J.S (1999) Male contraception: present and future (eds) NewDelhi: New age international. pp 177-188.

Bhasin, S., Fielder, T., Peacock, N., Morish, W.A.S., and Swerdloff, R.S (1988) Dissociating antifertility effects of GnRH antagonist from its adverse effects on mating behavior in male rats. American J. Physiology, 254:84-91.

Carrol, N.V., Langelly, R.W., and Row, R. H (1956) Glycogen determination in liver and muscle by use of anthrone reagent. J. Biol. Chem.20, 583-593.

Chatterjee, A., Adhikary, P., Banerji, J., Choudhuri, D., Jana, S., and Gupta, S (1994) Antifertility effect of *Piper betle* Linn. (stalk) in adult male rats. J. Indian Chem.Soci. 71:81-84.

Chaudhary, A., and Singh, R.V (2006) Fertility regulation in male rats by implemented tetraazamacrocyclic compounds of iron (ii): synthetic, spectroscopic and applied aspects with toxicological screening. Bioinorganic Chemistry and Application. 1-10.

Chinoy, N.J., and Mehta, D (1999) Effects of protein supplementation and deficiency on fluoride- induced toxicity in reproductive organs of male mice. Fluoride. 32(4): 204-214.

Chinoy, N.J., Mehta, D., and Jhala, D.D (2005) Effects of different protein diets on fluoride induced oxidative stress in mice testis. Fluoride 38 40: 269-275.

Chinoy, N.J., Sheth, K.M., and Seethalakshmi, L (1982) Studies on reproductive physiology of animals with special reference to fertility control. Comp. Physiol. Ecol.7:325.

Connel, G.M., and Eis- Nes, K.B (1968) Testosterone production by rabbit testis slice. Steroids, 12, 507.

Dawson, E.B., Harris, W.A., and Powell, L.C (1990) Relationship between ascorbic acid and male fertility. World Rev. Nutr. Diet. 62:1-26.

Dixit, V.P., and Bhargava, S.K (1983) Reversible contraception like activity of *Embelin* in male dogs (*Canis indicus* Linn). Andrologia. 15: 486-494.

Dixit, V.P., Gupta, C.L., Bhargava, and S.K., Sadhu, J.S (1979) Long term effect of metopiron (SU-4885 CIBA) on testicular function of dogs. Folia Biol. (Krakow) 27: 277-285.

Eik-Nes, K.B., and Hall, P.F (1962) Isolation of Dehydro epiandrosterone C14 from dogs infused with cholesterol 4C14 by the spermatic artery. Proc.Soc.Exp.Biol.Med.3:280-283.

Ghosesawar, M. G., Ahamed, N. R., Ahmed, M., and Aladdkatti, R.H (2003) *Azadirachata indica* Adversely affects sperm parameters and fructose levels in vas deferens fluid of Albino Rats . Basic and Clinical Physiology and Pharmacol. 14940, 387-395.

Giannini,E., Mansi, C., Dulbecco, P., and Savarino, V (2009) Role of partially hydrolyzed guar gum in the treatment of irritable bowel syndrome.*Nutrition*, Volume 22, Issue3, Pp.334-342.

Grooph, P.H., Aro, A., Stenman, S., and Groop, L (1993) Long term effects of Guar gum in subjects with non-insulin –dependent diabetes mellitus. Am. J. Clin. Nutr. Oct; 58(4); 513-8.

Gupta R.S., Kachhawa, J.B.S., and Rakhi Sharma (2006) Antispermato-genic effects of *Nyctanthus arborescens* in male albino rats. Pharmacology online. 2: 261- 273.

Gupta, R.S., Chaudhary, R., Yadav, R.K., Verma, S.K. and Dobhal, M.P (2005) Effects of saponins of *Albizia lebbek* (L.) benth bark on the reproductive system of male albino rats. J. Ethnopharmacol.96:31-36.

Gupta, R.S., Chaudhary, R., Yadav, R.K., Verma, S.K and Dobhal, M.P (2005) Effects of saponins of *Albizia lebbek* (L.) benth bark on the reproductive system of male albino rats. J. Ethnopharmacol.96:31-36.

Gupta, R.S., Sharma, R., Sharma, A., Bhatnager, A.K., Dobhal, M.P., Joshi, Y.C. and Sharma, M.C., (2002) Effect of *Alstonia scholaris* bark extract on testicular function of Wistar rats. Asian J. Androl., 4, 175-178.
Kabir, I.G., Yagen, B., Penhasi, A., and Rubinstein, A (1998) Low swelling, cross linked guar and its potential use as colon specific drug carrier. Pharmaceutical Research, Vol.15, No. 7.

Kantak, N .M., and Geogate, M.G (1992) Effect of short term administration of tulsi (*Ocimum sanctum* Linn) on reproductive behavior of adult male rats. Indian J. physiology and Pharmacolgy. 36, 106-111.

Keel, A. B., and Abney, T (1980) Influence of bilateral cryptorchidism in the mature rat; Alteration in testicular function and serum hormonal level. Endocrinology; 107: 1226-1233.

Kumari, V. G., Manonyaki, S., Padma, S., and Malini, T (1989) Antifertility effect of *Bambusa arundinacea* shoot extracts in male rats. J. Ethnopharmacol. 25, 173-180.

Lohiya, N. K., and Goyal, R.B (1992) Antifertility investigations on the crude chloroform extract of *Carica papaya* Linn seeds in albino male rats. Ind. Pharmacognosy. 30, 308-320.

Lowry, O.H., Rosenbrough, N.J., Farr.A.L., and Randall, R.J (1951) Protein measurement with the folin phenol Reagent.J.Biol.Chem.193(1): 265-275.

- Mishra R.K., and Singh S.K 2009 Antispermato-genic and antifertility effect of fruits of *Piper nigrum* L., in mice. Indian Journal of Experimental biology. 47, pp 706 – 714.
- Montanari, T., Carvalho, J.E.D., and Dolder, H (1998) Antispermato-genic effect of *Achillea millefolium* L. in mice. Contraception. 58, 309-313.
- Murugan, K., Kumari, V.G., and Sampathraj, R (1993) Effect of combined extracts of *Dolichos biflorus* seeds and *Amaranthus spinosus* roots on the accessory sex organs of male rats. Ancient Sci. Life. 12, 351-3.
- Murugavel., Rukunudin, A., Thangavelu, S., and Akbarsha, M. A (1989) Antifertility effect of *Vinca rosea* (linn) leaf extract in male mice sperm parametric study. Curr. Sci. 58, 1102-1103.
- Peters, J.P., and Vanslyke, D.D (1946) Quantitative Clinical Chemistry, Vol. I. Williams and Wilkins, Baltimore.
- Rao, M.V. (1988) Effect of alcoholic extract of *Solanum xanthocarpum* seeds in adult male rats . Indian J. Exp. Biol. 26, 95-98.
- Rao, M.V., and Mathur, N (1988) Estrogen induced effects on mouse testis and Epididymal spermatozoa. Experimental and clinical Endocrinology. 92, 231-234.
- Rao, M.V., and Shah, K.D (1988) Endocrine approach to male fertility control by steroid hormone combination in rat *Rattus Norvegicus*. L. Indian journal of Expt Biol; 36: 775-779.
- Roe, J.H., and Kuether, C.A (1943) The determination of ascorbic acid in whole blood and using through the 2-4 dinitrophenyl hydrazine derivative of dehydroascorbic acid. J. Biol. Chem. 147, 399-407.
- Rommerts, F.F.G., Cooke, B.A., and Vander Molen, H.J (1974) The role of cyclic AMP in the regulation of steroid biosynthesis in testis tissue. J. Steroid. Biochem. 5, 279.
- Sailani, M.R., and Moeini, H (2008) Effect of *Ruta graveolens* and *Cannabis sativa* alcoholic extract on spermatogenesis in the adult Wistar male rats. Indian J. of Urology. pp 257- 260.
- Sarkar, H.B.D (1996) Principles of vertebrate reproductive biology. Ganapathy Graphics, pp 320-362.
- Setty, B.S (1979) Regulation of Epididymal function and sperm maturation- endocrine approach to fertility control in male. Endocrinology. 74, 100-117.
- Sharma, S., Kumar, M., Goyal, R.B., Manivannan, B., and Lohiya, N.K (1999) Reversible antispermato-genic effect of Gossypol in longur monkeys (*Presbytis entelle entellus*). Adv. Contraception. 15, 15.
- Shkukani, H.G., Salhab, A.S., Disi, A.M., Shomaf, M.S., and Quadani, F.A (2007) Antifertility effect of ethanolic extract of *Juniperus phoenicea* (L.) in male albino rats. J. herbal Pharmacol. ther. 7 (3-4): 179-189.
- Singh, A., and Singh, S.K (2008) Reversible antifertility effect of aqueous leaf extract of *Allamanda cathartica* L. in male laboratory mice. Andrologia. Vol 4 (6), pp 337-345.
- Sondersten, P (1979) Role of Estrogen in the Display and Development of Sexual Behaviour in Male Rats. In: Beyer, C. (Ed.), Raven Press, New York, pp. 305–315.
- Udoh, P., and Kehinde, A (1999) Studies on antifertility effect of Pawpaw seeds (*Carica papaya*) on the gonads of male albino rats. Phytother res. 13, 226-228.
- Vega, S.G., Guzman, P., Garcia, L. Espinosa, J., and Denova C.C (1988) Sperm shape abnormality and urine mutagenicity in mice treated with niclosamide, Mutat. Res. 204(2), 269–276.
- Vijaykumar, B., Sangamma, I., Sharanabassappa, A., and Patil, S.B (2004) Antispermato-genic and hormonal effects of *Crotalaria juncea* linn. Seed extracts in male mice. Asian J. Androl. 6:67-70.
- WHO task force on methods for the regulation of male fertility. (1990) Contraceptive efficacy of testosterone induced azoospermia in normal men. Lancet. 336: 955 – 959.
- Wilke T J., and Utley D J (1978) Total testosterone, Free androgen index, Calculated free testosterone and free testosterone by analog RIA compared in hirsute women and in otherwise normal women with altered binding of sex hormone- binding globulin. Clin Chem- 33:8.
- Zeherea, M .N., Reddy, S. P., Reddy, S. P., Ravindra., and Saraswati, B. Patil (1998) Antispermato-genic and androgenic activities of *Momordica Charantia* (Karela) in albino rats. J. Ethnopharmacol. 61, 9- 16.