



ULTRASTRUCTURAL PATHOLOGY OF OCHRATOXIN AND CITRININ TOXICOSIS IN BROILER CHICKEN

^aJayaramu G.M., ^bSatyanarayana M.L., ^cRavikumar, P. and ^dLakshman, M.

^aDepartment of Veterinary Pathology, Veterinary College, Hassan - 573201, KVAFSU, Karnataka

^bDepartment of Veterinary Pathology, Veterinary College, Bangalore – 560024, KVAFSU, Karnataka

^cDepartment of Veterinary Pathology, Veterinary College, Hassan - 573201, KVAFSU, Karnataka

^dDepartment of Veterinary Pathology, Veterinary College, Rajendranagar, Hyderabad, A.P

ABSTRACT

The study was undertaken to evaluate the effect of feeding ochratoxin A and citrin either alone or in combination in broiler chicken. Two hundred broiler chicks were divided into four groups of 50 chicks each with the following treatment viz. Control diet, (group I), OA 1 ppm, (group II), CTN 12.5 ppm (group III) and combination 1 ppm OA plus 12.5 ppm CTN (group IV) up to 35 days of the trial. The experimental and the control birds were sequentially sacrificed and examined at 21 and 35th day of the experiment. Transmission electron microscopic studies were carried out on liver, kidneys, spleen, bursa of Fabricius and thymus in birds of all the dietary treatment groups (Group I to IV) on day 21 and 35 of the experimental study. Ultrastructurally, the toxin fed birds showed vacuolation of cytoplasm, swollen mitochondria with granular matrix, condensation of chromatin material / nucleolus and granular nucleolemma in liver. Loss of brush border in proximal convoluted tubules, vacuolation of cytoplasm of epithelial cells, condensation of nucleus and mild swollen mitochondria in kidneys. Vacuolation of cytoplasm of spleenocyte mild to moderate margination of chromatin and chromatolysis in spleen. Condensed nucleus, clear vacuolation of B lymphocytes, pyknotic with mild vacuolation and necrosis of bursal epithelial cells in bursa of Fabricius. Swollen corpuscles, karyorrhexis and disintegration of nuclear material and moderate margination of chromatin material in Thymus. Severity of these lesions was found to be enhanced and suggested the additive or synergistic effect of these toxins in the broiler chicken.

KEYWORDS: ochratoxin A, citrinin toxicity, broiler chicken, ultrastructural pathology.

INTRODUCTION

Mycotoxins comprise a structurally diverse family of naturally occurring fungal toxins, which directly or indirectly contaminate the feed of livestock and poultry resulting in toxicities. In poultry, mycotoxicosis causes reduced growth rate, lowered feed conversion, impaired resistance to infectious disease and reduced vaccination efficacy with lesions in many organs (Coulombe, 1993). Exposure to low concentration of Ochratoxin A through diet is known to cause structural and functional changes in different organ systems, especially the kidneys and liver of several domestic and experimental animals^{2,6}. Citrinin is known to be nephrotoxic besides affecting the growth and productivity of birds^{1,7,8}. Ochratoxin and citrinin may occur as co-contaminants of feed and feed ingredients. Considering the effects of these mycotoxins on health and performance of birds as well as huge economic losses involved the present work was taken up to study in detail the effect of individual and combined toxicosis of ochratoxin and citrinin in broilers.

MATERIAL AND METHODS

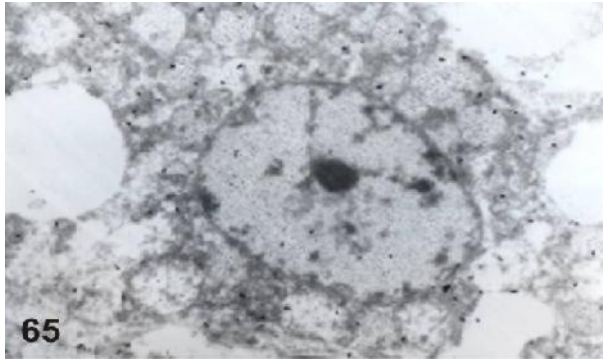
Unsexed, day old Vencobb broiler chicks (200 numbers) were obtained from M/S Akash Hatcheries, Bangalore. They were provided with optimum conditions of brooding and management. Poultry mash, both starter and finisher without addition of toxin binder. They were tested for the presence of mycotoxins such as Aflatoxin, ochratoxin and citrinin. After ascertaining the mycotoxin free status of the

feed, they were kept in individual labeled bins for further use. On day one of age, the broiler chicks were randomly divided into four different dietary treatment groups of 50 birds each viz., Group I, fed standard mycotoxin free basal diet (control), Group II, diet containing 1 ppm OA, Group III, diet containing 12.5 ppm CTN, Group IV, diet containing 1 ppm OA plus 12.5 ppm CTN. Six birds from each group were sacrificed on day 21 and 35th day of the experiment. Transmission electron microscopic studies were carried out on liver, kidneys, spleen, bursa of Fabricius and thymus in birds of all the dietary treatment groups (Group I to IV) on day 21 and 35 of the experimental study. The broiler chicken sacrificed during the course of experiment, were systematically necropsied and gross lesions were recorded. For electron microscopic studies, tissue samples collected were transferred to vials and fixed in 3% Gluteraldehyde in 0.05 M. phosphate buffer (pH 7.2) for 24 hrs at 4°C and post fixed with 2% aqueous Osmium tetroxide in the same buffer for 2 hrs. After the fixation, the samples were dehydrated in a series of graded acetone and infiltrated and embedded in Araldite 6005 resin. Semi thin sections (300-500 nm) and Ultra thin sections (50-70 nm) were cut with a glass knife on a Leica Ultra cut (UCT-GA-D/E-1/00) microtome. Semi thin sections were stained with toluidine blue and studied under light microscope (Olympus AX-70). Ultra thin sections were mounted on grids and stained with saturated aqueous Uranyl acetate and counter stained with 4% lead citrate. The sections were observed under transmission electron

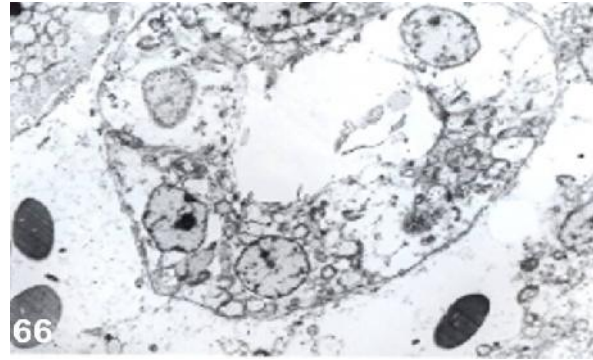
microscope (Model: Hitachi, H-7500) at various magnifications and photographs were taken at RUSKA Labs, College of Veterinary Science, SVVU, Rajendra Nagar, Hyderabad, India.

RESULTS & DISCUSSION

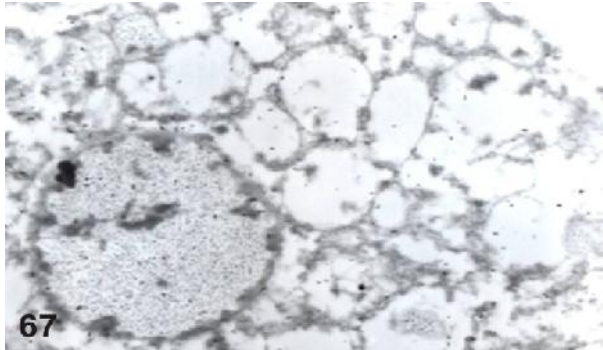
Ultrastructural examination of liver section in Group II birds revealed vacuolation of cytoplasm, swollen mitochondria with granular matrix, condensation of chromatin material / nucleolus and granular nucleolemma (Plate 1). Examination of kidney section revealed loss of brush border in proximal convoluted tubules, vacuolation of cytoplasm of epithelial cells, condensation of nucleus and swollen mitochondria (Plate 2).



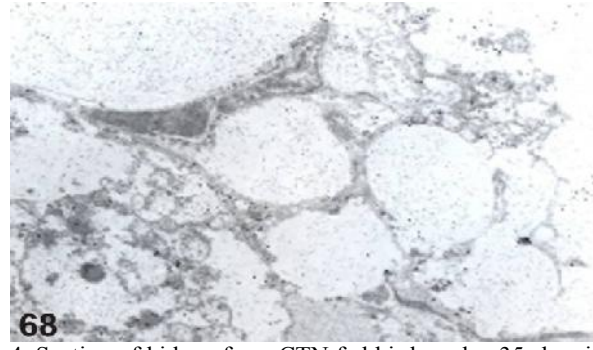
1. Section of liver from OA fed bird on day 35 showing vacuolation of cytoplasm, swollen mitochondria with granular matrix, condensation of chromatin material / nucleolus and granular nucleolemma. Uranyl acetate - Lead citrate stain x 8950.



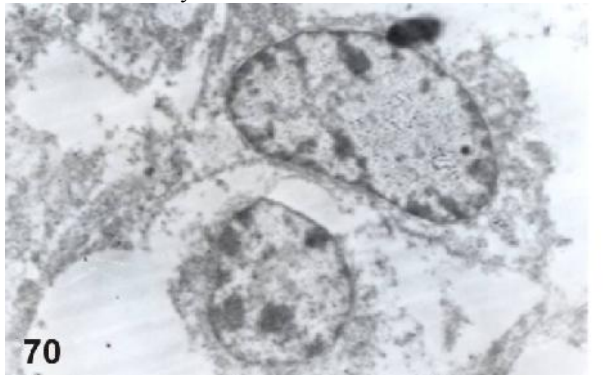
2. Section of kidney from OA fed bird on day 35 showing loss of brush border in proximal convoluted tubules and vacuolation of cytoplasm of epithelial cells. Uranyl acetate - Lead citrate stain x 3580.



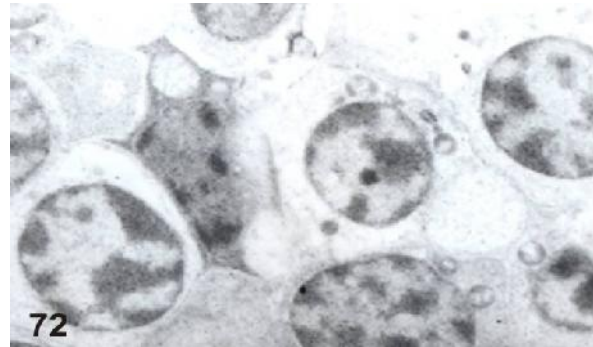
3. Section of liver from CTN fed bird on day 35 showing vacuolation of cytoplasm, condensation of nucleolus, granular nucleolemma, indistinct outer inner nuclear membrane. Uranyl acetate - Lead citrate stain x 10740.



4. Section of kidney from CTN fed bird on day 35 showing prominent vacuolation of cytoplasm, swollen mitochondria with partial margination of chromatin material. Uranyl acetate - Lead citrate stain x 6265.



5. Section of spleen from 21 day old bird fed with a combination of OA and CTN showing margination of chromatin and chromatolysis. Uranyl acetate - Lead citrate stain x 8950.



6. Section of thymus from 21 day old bird fed with a combination of OA and CTN showing swollen thymus corpuscles, karyorrhexis and disintegration of nuclear material and moderate margination of chromatin material. Uranyl acetate - Lead citrate stain x 8950.

These results suggested that the mitochondria in the proximal convoluted tubules of kidney were most sensitive to OA toxicity. Similar observation were also made in broiler chicks^{3,5} fed with OA in the diet. Ultrastructurally, the liver sections in Group III birds revealed vacuolation of cytoplasm, swollen mitochondria, granular matrix, condensation of nucleolus, granular nucleolemma and indistinct outer and inner nuclear membrane (Plate 3). The kidney section revealed vacuolation of cytoplasm in the PCTs, swollen mitochondria with granular matrix, loss of cristae, chromatolysis, clumping of RER (granular) and partial margination of chromatin material (Plate 4). Similar observation were also made in broiler chicks^{1,3} fed with CTN in the diet. Electron microscopic examination of liver in Group IV birds revealed irregular glycogen granules, karyorrhexis and margination of chromatin, rhexis of nucleus and clumping of granular EPR, vacuolation of cytoplasm, granular nucleolemma and loss of nucleolus, dilated intercellular hepatocyte junctions, clumping of nuclear material, swollen mitochondria with granular matrix. Similar observation were also made in broiler chicks³ fed with OA and CTN in the diet. The spleen showed mild to moderate margination of chromatin and chromatolysis and vacuolation of cytoplasm (Plate 5). The bursa of Fabricius in combined toxicity group showed condensed nucleus, clear vacuolation of lymphocytes, pyknosis, vacuolation and necrosis of bursal epithelial cells. The thymus showed swollen corpuscles, karyorrhexis and disintegration of nuclear material and moderate margination of chromatin material (Plate 6). It may be concluded that the extensive nuclear and mitochondrial damage may reflect the way in which these toxins damage cell membrane and organelles leading to altered protein synthesis and associated immune dysfunction.

REFERENCES

- Anandkumar (2006) Pathological study on the combined effect of citrinin and aflatoxin in broiler chicken. Ph.D. thesis, Univ. TANUVAS, Chennai.
- Anitha (2007) Pathology of ochratoxicosis and its amelioration with herbal oil and toxin binder in broiler chicken. M.V.Sc. thesis. Univ. KVAFSU, Bangalore.
- Brown, T.P., Manning, R.O., Fletcher, O.J. and Wyadd, R.D. (1986) The individual and combined effect of citrinin and ochratoxin A on renal ultrastructure in layer chicks. *Avian Dis.*, **30**(1): 191-198.
- Coulombe, R.A. (1993) Biological action of mycotoxins. *J. Dairy Sci.*, **76**: 880-891.
- Dwivedi p, Burns, R.B. and Maxwell M.H. (1984) Ultrastructural study of the liver and kidney in ochratoxicosis A in young broiler chicks. *Res. Vet. Sci.*, 1984.
- Kumar, A., Jinda, N., Shukla, C.L., Yash pal, Ledoux, D.R. and Rottinghaus, G.E. (2003) Effect of ochratoxin A on *E. coli* - challenged broiler chickens. *Avian Dis.*, **47**: 415-424.
- Swaminathan, B. (2002) Individual and combined effect of ochratoxin A and citrinin toxicity in broilers. M.V.Sc. thesis, TANUVAS, Chennai.
- Uma, M. and Reddy, M.V. (1995) Citrinin toxicity in broiler chicks. Haematobiochemical and pathological studies. *Indian J. Vet. Pathol.*, **19**(1): 11-14.