



NEWCASTLE DISEASE AND INFECTIOUS BRONCHITIS DISEASE VACCINATION PROGRAMS IN FIELD STUDY

S. M. A. AL-Gburi

Department of Pathology College of veterinary medicine Univ. of Baghdad, Iraq.

ABSTRACT

This experiment was conducted by using (32000) chicks classified into three houses (18000 chicks in first house, 5000 chicks in second house and 9000 chicks in third house). The first group was inoculated with inactivated oil emulsion vaccine contain NDV (La Sota) and AIV (H9N2) subcutaneous at one day, in the same time vaccinated with mixed vaccine of NDV (La Sota) and IBV H120 by spraying route followed by booster dose by the same vaccine (NDV (La Sota) and IBV H120) at day 5 via drinking water and at the eighteen day vaccinated with IBV H120 via drinking water, while the second group vaccinated with mixed vaccine (NDV (La Sota) and IBV H120) at one day by spray route, at ten day vaccinated with inactivated oil emulsion vaccine contain NDV (La Sota) and AIV (H9N2) injection subcutaneous and the same time vaccinated with NDV (La Sota) by spray route, where as the third group was vaccinated with inactivated oil emulsion vaccine contain NDV (La Sota) and AIV (H9N2) injection subcutaneous at fifth day in the same time vaccinated with mixed vaccine from NDV (La Sota) and IBV H120 by droplet route in eyes and at the eighteen day vaccinated with IBV H52 via drinking water. ELISA test and Histopathological examination were used to evaluated the immune response against NDV and IBV, the results revealed high antibody (Ab) titres against IBV in first group that received more one mixed vaccine but give pathological changes in trachea and kidney as compared with other group that give low titre with least histological changes.

KEY WORDS: chicks, NDV (La Sota), IBV H120, AIV (H9N2). AIV (H9N2).

INTRODUCTION

Respiratory diseases of poultry remain of major importance. Many of these diseases or infections once re-emerging or introduced into a geographic area can explode into an epidemic and may have a significant negative effect on international trade. Respiratory diseases as Newcastle (ND), infectious bronchitis (IB) are continuing to cause high economic losses in many areas world-wide duo to increased mortality rates, decreased weight gain, increased medication costs and increased feed conversion rates [1]. Newcastle disease virus became endemic in Iraq [2] causing great economic losses due to high mortality rates, reduction of meat and drop in egg production [3]. Infectious Bronchitis disease is an acute contagious disease of chicken characterized primarily by respiratory signs, and allows secondary invasion of the lungs and air

sacs with bacterial infections which is mostly accompanied with significant losses due to condemnation at slaughter. Weight gain and feed conversion efficiency may be impaired as well as problems in egg production [4]. Respiratory diseases of chicken due to mixed infections by different organisms are very common, therefore, using of either bivalent, trivalent or polyvalent vaccines were preferable than that of monovalent vaccines for prevention of the common respiratory diseases as well as they have the advantages of reducing vaccination expenses and saving time and labor costs [5]. Earlier studies have reported that infectious bronchitis virus (IBV) interferes with the immune response against Newcastle disease virus (NDV) [6]. The aim of the present study is to evaluate the best vaccination programs against Newcastle disease virus and infectious bronchitis virus to protect chickens.

TABLE 1: Strains used in vaccination programs.

Strain	Titer	Source (Origin)
Inactivated oil vaccine (NDV and AIV "H9N2")	NDV La Sota $10^{9.0}$ EID ₅₀ AIV H9N1 $10^{7.5}$ EID ₅₀	Heinz-Lohman-Germany
IBV H120	IBV H120 10^3 EID ₅₀	Heinz-Lohman-Germany
IBV H52	IBV H52 10^3 EID ₅₀	Heinz-Lohman-Germany
(NDLa Sota)/(IBV H120)	NDV La Sota 10^6 EID ₅₀ IBV H52 10^3 EID ₅₀	Heinz-Lohman-Germany
ND La Sota	NDV La Sota 10^6 EID ₅₀	Heinz-Lohman-Germany
IBDV strain LC75	IBDV 10^3 EID ₅₀	Heinz-Lohman-Germany

MATERIALS & METHODS

Vaccine Strains

Application three vaccination programs for NDV and IBV diseases on to three broiler houses at one day, the first house include 18000 (rose breed) broiler chicks in the Al-wahda region, vaccinated with inactivated oil emulsion vaccine contain NDV (La Sota) and AIV (H9N1) injection subcutaneous at one day, in the same time vaccinated with mixed vaccine of NDV (La Sota) and IBV H120 by spraying route followed by booster dose from the mixed vaccine (NDV (La Sota) and IBV H120) at day 5 via drinking water and at the eighteen day vaccinated with IBV H120 via drinking water, While the second house in the Al-madian region included 5000 (rose breed) broiler chicks vaccinated with mixed vaccine (NDV (La Sota) and IBV H120) at one day by spraying route, at ten days vaccinated with inactivated oil emulsion vaccine contain NDV (La Sota) and AIV (H9N2) injected subcutaneous and the same time vaccinated with NDV (La Sota) by spraying route. Whereas the third house placed in Al-suara region include 9000 (rose breed) broiler chicks was vaccinated with inactivated oil emulsion vaccine contain

NDV (La Sota) and AIV (H9N2) injected subcutaneous at fifth day in the same time vaccinated with mixed vaccine from NDV (La Sota) and IBV H120 by droplet route in eyes and at the eighteen day vaccinated with IBV H52 via drinking water. All groups were vaccinated with IBDV at thirteen days. Blood samples from each group were aspirated from jugular vein to determine Ab titers against IB and NDV at 35 day by using ELISA test. Samples were collected from internal organs included (kidney, trachea, thymus, bursa of fabricius, spleen and cecal tonsil) for gross and histopathological study at day 35.

RESULTS

Results of ELISA test for chicks against IB at 35 day-old:

ELISA result showed the presence of significant differences ($P < 0.05$) in Ab titer between the first and the second groups in which the highest mean value observed in the first group was raised to reach (1774) but the second group was (618), but no significant differences ($P < 0.05$) in Ab titer between the (first, second) with third group (951.6).

TABLE 1. Results of ELISA titer against IB disease at (35) days old

Group	G1	G2	G3
Mean ± SE	1774 ± 117.74	618.6 ± 52.15	951.6 ± 36.41
	A	B	A

The differences in capital letters vertical refer to presence of significant value at ($P < 0.05$).

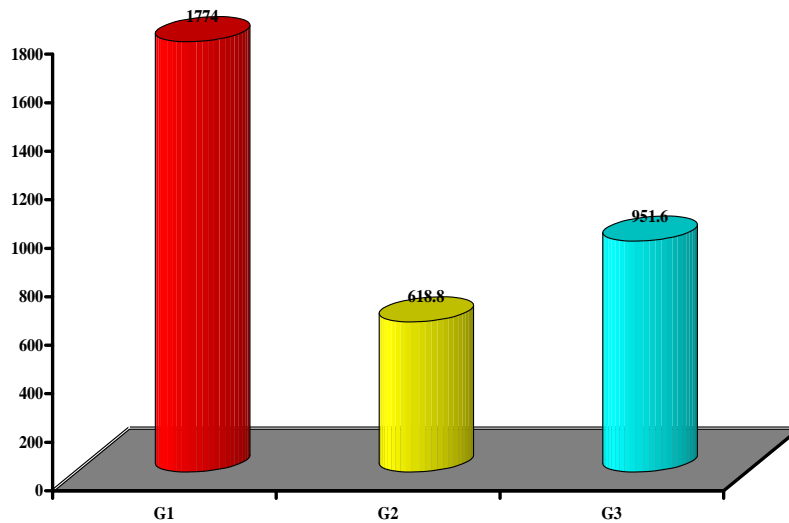


FIGURE 1. Results Ab titer against IB at 35 days old measured by ELISA.

Results of ELISA test for chicks against ND at 35 day-old

Also result showed the presence of significant differences ($P < 0.05$) in Ab titer in which the highest mean value

observed in the second group which raised to reach (3552), followed by the third and the first groups (2350 and 1951) respectively.

TABLE 2. Results of ELISA titer against ND disease at (35) days old

Group	G1	G2	G3
Mean ± SE	1951 ± 206.26	3552 ± 392.02	2350 ± 125.35
	B	A	B

The differences in capital letters vertical refer to presence of significant value at ($P < 0.05$).

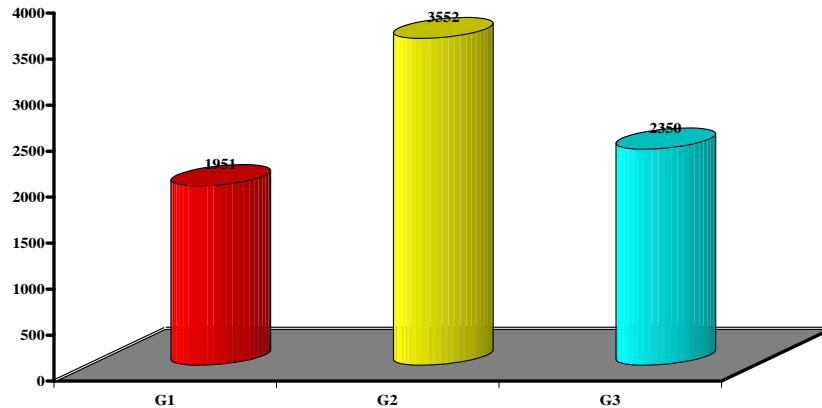


FIGURE 2. Results Ab titer against ND at 35 days old measured by ELISA.

Interference in Ab titer between IB and ND

The results refer to the presence of a negative interaction ($P < 0.05$) in the mean values of Ab titer between IB and ND at 35 days, so that there is a significant increase ($P < 0.05$) in Ab titer (1774) by ELISA test against IB in the

first group, while there is a significant decrease ($P < 0.05$) in mean value of Ab titer (1951) by ELISA against ND in the first group. Also the other vaccinated groups record a negative interaction ($P < 0.05$) in the mean values of Ab titer between IB and ND at 35 days.

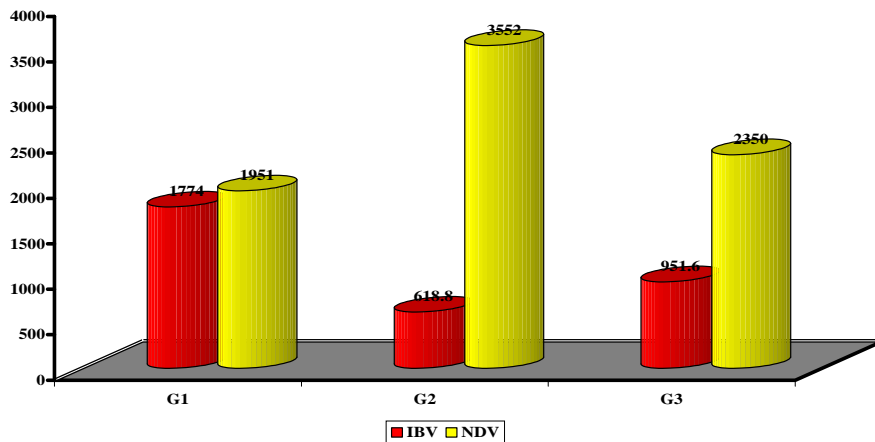


FIGURE 3. Results of a comparative study between mean of Ab titer against ND and IB at 35 day-old by ELISA

Macroscopically findings

Histopathological examination of certain organs included (bursa, thymus, spleen, trachea and kidney) were carried out at 35 days old chicks.

Bursa of fabricius

There is depletion the lymphocyte and oedema in the centre of the lymphoid follicles (fig. 1). this lesion can be seen in first and third group, while the second group showed the few infiltration of lymphocyte at the centre of lymphoid follicles with formation the germinal centre (fig. 2).

Thymus

There is a moderate hyperplasia of lymphoid follicles with increment in their number and size (fig. 3). These observations were recorded in the first and third vaccinated groups, while there is severe hyperplasia of lymphoid follicles with formation of germinal centers in the second vaccinated group with formation of germinal centre as in (fig. 4).

Trachea

demonstrated marked lesions were noticed in the first group characterized by diffuse infiltration of sub epithelial and deep layer of mucosa with lymphocytes and histiocytes (fig. 5) resulted an increase in thickness of mucosa, also there is congestion to the blood vessels of mucosa this lesion was seen in first vaccinated group, however the second and third groups showed marked lymphoid tissue hyperplasia which appear in lamina propria (fig: 6)

Kidney

Slight infiltration of lymphocyte in multiple areas in the interstitial connective tissue of cortical area in certain chicks, the renal tissue illustrated multiple areas of aggregation of lymphocytic cells in interstitial tissue around the blood vessel (fig. 7) those alterations were watched just in the first group whereas the second and third groups showed multiple focal area of lymphocyte aggregation in the interstitial connective tissue (fig. 8).

Spleen

Show Slight follicular lymphoid hyperplasia (fig. 9) this lesion can be seen in first vaccinated group, while the

second and third group showed sever hyperplasia in lymphoid follicle as in (fig. 10).

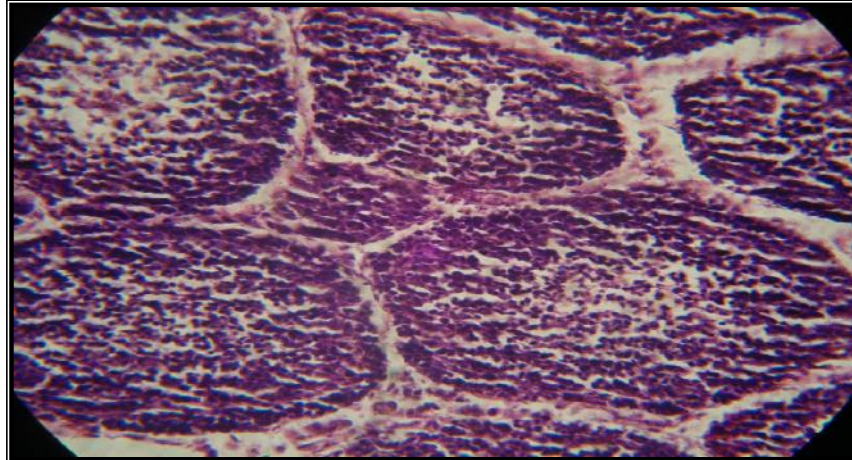


FIGURE 1. Histopathological section in bursa of fabricius at 35 day-old chicks showed depletion the lymphocyte and oedema in the centre of the lymphoid follicles in first and third group (H and E 40X).

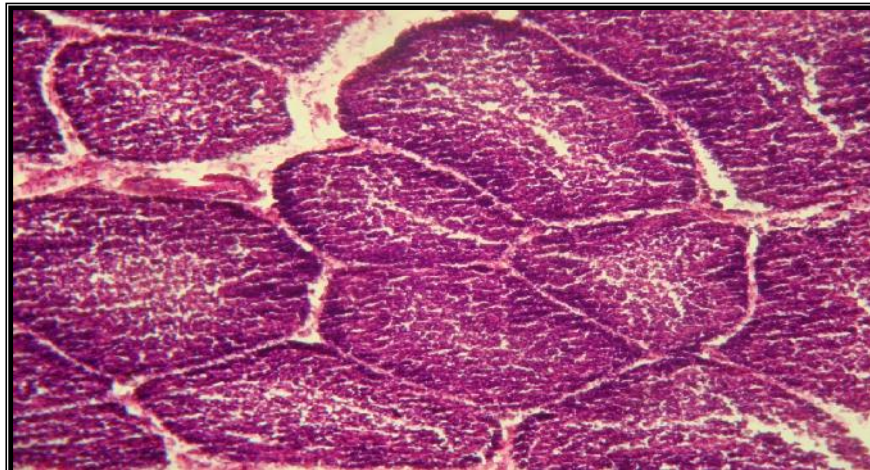


FIGURE 2. Histopathological section in bursa of fabricius at 35 day-old chicks showed severe hyperplasia of lymphoid follicles with formation of germinal centers in second group (H and E 40X).

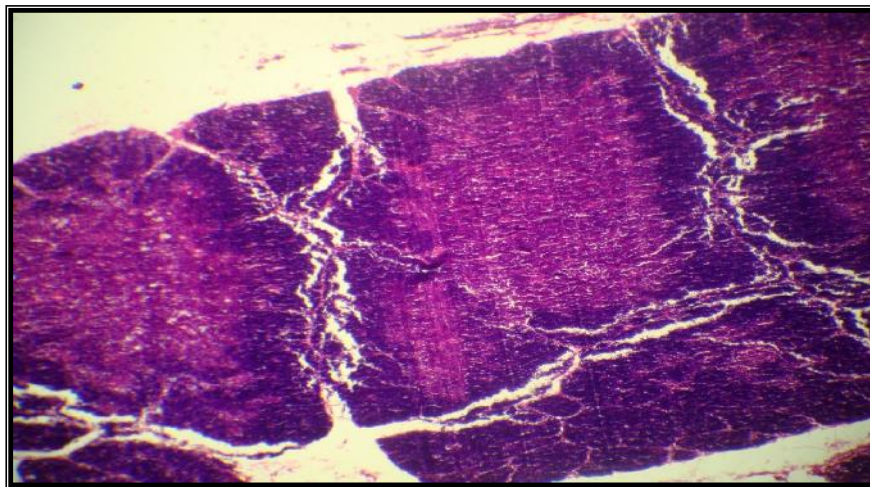


FIGURE 3. Histopathological section in thymus at 35 day-old chicks showed there is moderate lymphocytic hyperplasia in the cortex with proliferation of mononuclear cells around the sinus of the medulla and moderate thickness of trabeculae in first and third group (H and E 40X).

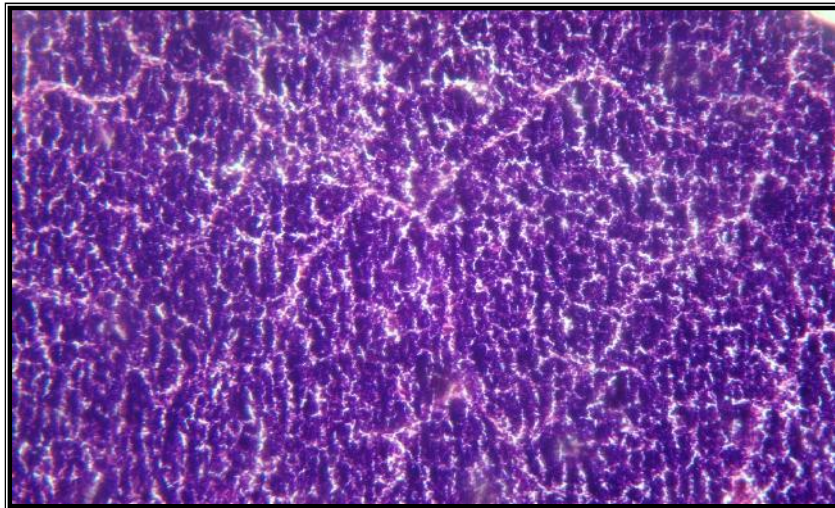


FIGURE 4. Histopathological section in thymus at 25 day-old chicks showed severe hyperplasia of lymphoid follicles with increase in their number and size with formation of germinal center second group (H and E 40X).

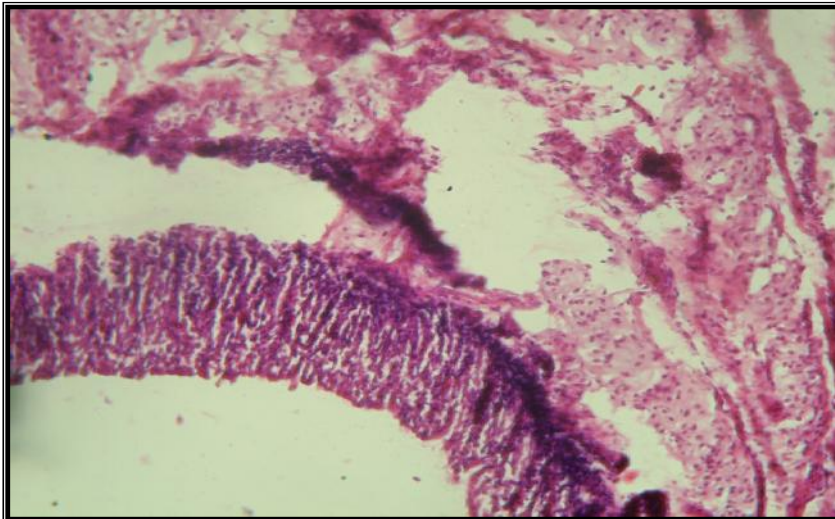


FIGURE 5. Histopathological section in trachea at 35 day-old chicks showed subepithelial and deep layer of mucosa with lymphocytes and histiocytes, special in first group (H and E 10X).

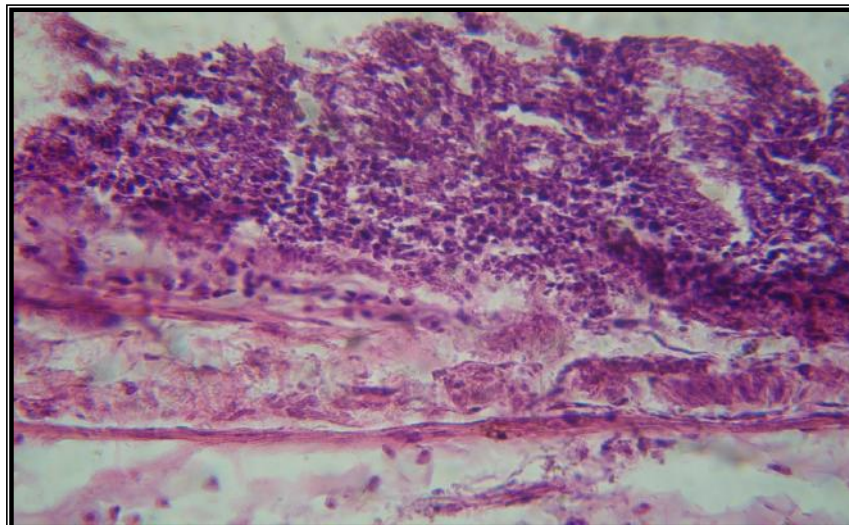


FIGURE 6. Histopathological section in trachea at 35-day-old chicks showing increased thickness of mucosa due to infiltration of mononuclear cells in the epithelial and subepithelial tissue, in the second and third group (H and E 40X).

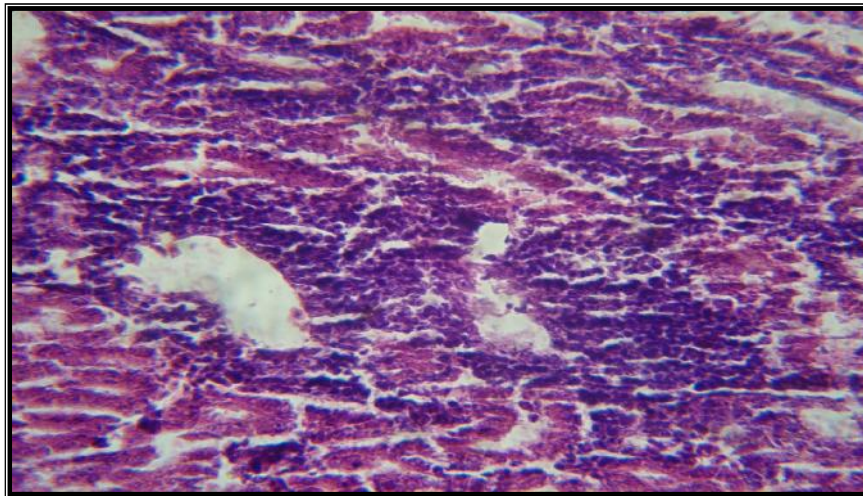


FIGURE 7. Histopathological section in kidney at 35 day-old chicks showed multiple areas of lymphocytic aggregation in the intertubular connective tissue of cortical area with congestion of blood vessels in first group (H and E 10X).

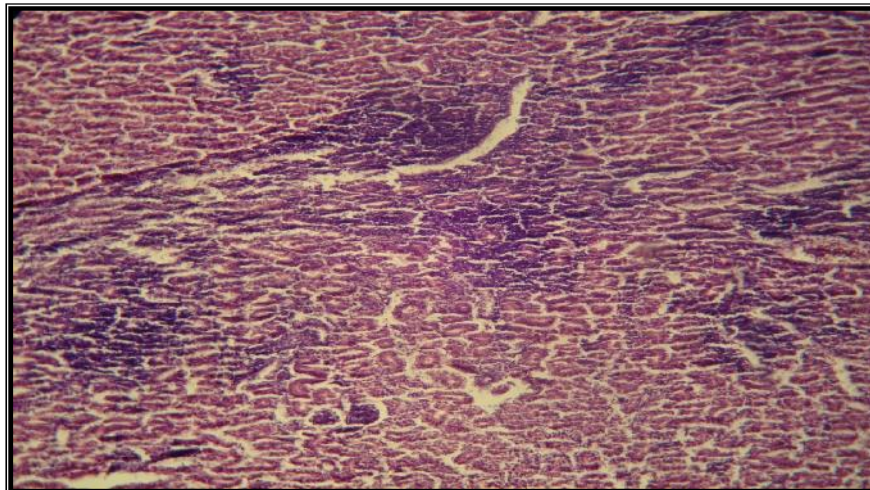


FIGURE 8. Histopathological section in kidney at 35-day-old chicks showed multiple focal aggregations of mononuclear cells with increase in the thickness of interstitial tissue due to infiltration of lymphocytes special in second and third group (H and E 40X).

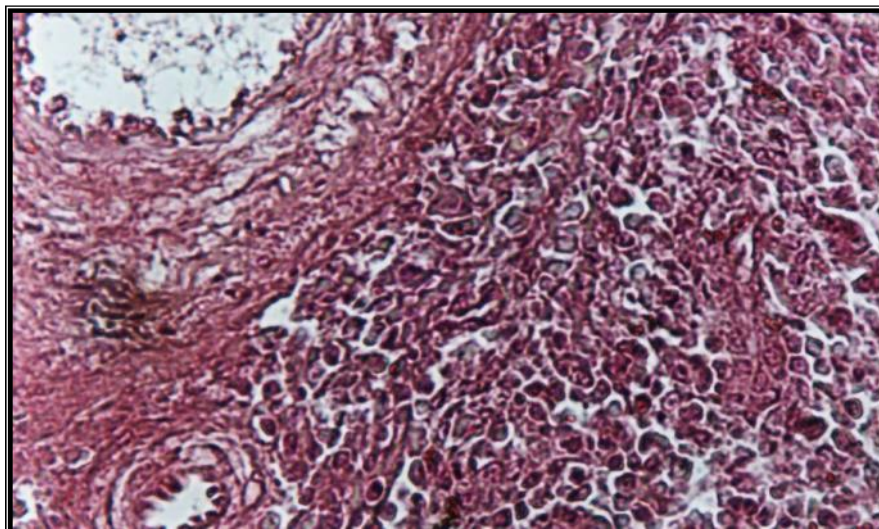


FIGURE 9. Histopathological section in spleen at 35-day-old chicks showed multiple focal aggregations of mononuclear cells with increase in the thickness of interstitial tissue due to infiltration of lymphocytes special in first group (H and E 40X).

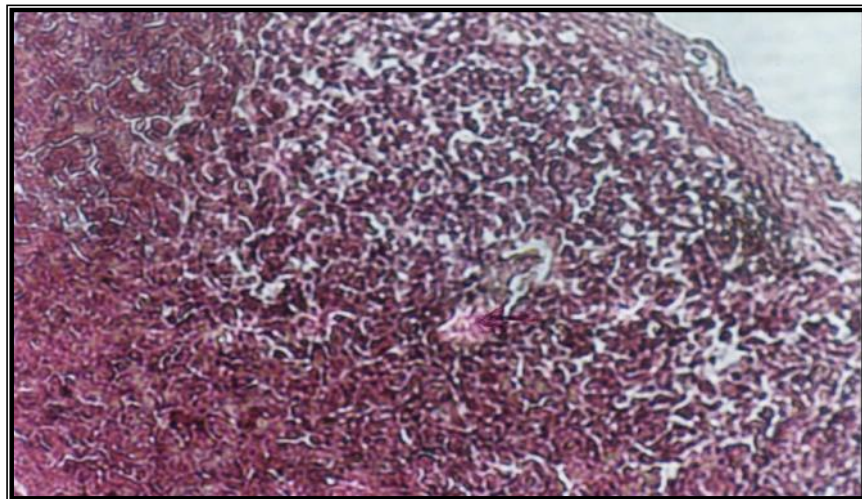


FIGURE 10. Histopathological section in spleen at 35-day-old chicks showed sever hyperplasia in lymphoid follicles special in second and third group (H and E 40X).

DISCUSSION

On the 35 days of age, results indicated that's groups with more frequent IB vaccination had higher antibody titer so that group first (3 times mixed vaccination) had the maximum antibody titer ($P < 0.05$) (table: 1). At the same age, groups received mixed vaccine had numerically higher antibody titer as compared to the groups received IB vaccine alone, in this regard, the results show significant difference between groups first, second and third that received mixed vaccine by different routs (spraying, drinking water, eyes droplet), this might be due to the increased histopathologic lesions in the trachea of the treatment groups, which assist to increased immune response, Administration of mixed vaccine has demonstrated to induce deciliation, hyperplasia, hyperemia, and some lesion in the tracheal epithelial mucosa [7]. There is a considerable variation in response in birds to mixed vaccines. [8] reported that this variation was associated to the IBV strain, The only exception in this case was first group that receiving more times of mixed vaccine including (NDV (La sota strain), IBV (H120)). In general (with some exception), trend changes in IgA titers were similar to that observed in systemic antibody titers. [9] studied the immune response induced by live mixed NDV (La sota) and IBV (H120, H52) vaccines. The results showed that simultaneous use of these three vaccines had not any positive or negative effects on the immune response as compared to the administration of single or combined vaccines. [4] Cavanagh, D. and Nagi, S. A. have declared that excess IBV particles in the vaccine interference with NDV immune response. By virtue of this, it is suggested that combine vaccine are preferred to mixed single vaccines [10]. As a general rule, it is indicated that two distinct live vaccines should not be mixed for use and it ought to be administrated separately with 14 (at least 7) days interval to avoid any possible interference [10]. It has been recently shown that mucosal immunity in the respiratory system act as the first line of defense against the IBV challenge and resistance against IBV infections may be due to either tracheal mucosal immunity [11]. Or cell mediated immunity [12]. There are some repots indicating significant relationship between mucosal (local) IgA and

resistance against infection with IBV. Therefore, measuring local IgA could be a suitable alternative for monitoring the level of protection after IBV vaccination or infection [13]. In the other hand, the increased Ab titers in all immunized groups against NDV at day 35 were compared with the groups vaccinated with IBV which record decreased immune response, these findings correspond to those obtained by [14] who referred to the effect of the oil emulsion vaccine that plays an important role in the induction of immune organs to generate further Abs production. The results of the existing study agree with the studies of [6] who explained that the interference between IBV and NDV occurred because both of them infects initially the epithelial cells of respiratory tract and then replicates in the cell cytoplasm. Also agree with the studies performed by [15] using combined or IBV and NDV vaccinations showed that IBV vaccination causes a decrease in the capacity of the harderian gland to respond to antigenic stimulus. Therefore, the reduced immune response by harderian gland induced by IBV may then decrease anti-NDV antibody levels if vaccination has been performed with IB-ND combined vaccines. Cook *et al.* [10] reported that IBV interferes with NDV when mixed vaccine in field as compared with preparation in laboratory. The histological lesion that observation in (bursa of fabricius, thymus, trachea, kidney and spleen) These observations are in agreement with Kindt *et al.* [16] who explained the role of lymphocytes production and lymphoid hyperplasia in immune organs like (bursa of fabricius, thymus, harderian gland, spleen, peyer's patches) in determination the efficiency of immune response resulted from immunization against IBV, NDV and any foreign body.

REFERENCES

- [1]. Hafez, M.H. (2006) Respiratory diseases of poultry: diagnosis and control. 7 th Sci . Conf. of the EVPA . Pp.3- 10.
- [2]. Sheble, A. and Reda, I.M. (1976) Isolation and characterization of local viscerotropic Newcastle disease virus. unpublished data. 5(4): 58-76.

- [3]. Biswal, G. and Morrill, C.C. (1954) Newcastle disease virus Poult. ci. 33: 880 – 897.
- [4]. Cavanagh, D. and Nagi, S.A. (2003) Infectious Bronchitis in Diseases of Poultry, 11 th ed. Saif. Y.M., H. J. Barnes, J. R. Glisson, A. M. Fadly, L.R., McDougald, D.E. Swayne. (Eds.) Ames, Iowa State press a Blackwell publishing company- pp. 101 - 119.
- [5]. Soliman, S.A., Soliman, S. M., Gergis, S.M., Afaf, H.A., El-Said, A. and Abou-Zeid, A. (1995) Combined a virulent vaccine for Newcastle and fowl cholera diseases J. Egypt. Assoc. Immun. 1: 43 -46. 16.
- [6]. Gelb, J.Jr., Campion, L. and Ladman, B. (2004) Interferência na replicação entre os virus da bronquite infecciosa e da doença de Newcastle. In: Anais vol.1 da Conferência Apinco de Ciência e Tecnologias Avícolas. São Paulo-Brasil. : 63-70.
- [7]. Nakamura, K., Nartia, M., Imai, K., Matsumura, T., Maeda, M. and Tanimura, T. (1992) The effects of the live mixed vaccines of Newcastle disease and infectious bronchitis on the chicken respiratory tract. J. Comp. Pathol., N.106: 341-350.
- [8]. Smith, J.A. (2003) Impact of Newcastle vaccine on the IBV control. Poult. Digest. Online. 3: 1-14.
- [9]. Chalokova, R. (1985) Associated vaccination of poltry against infectious bronchitis, Newcastle disease and infectious bursitis. Vet. Med. 22: 32-38.
- [10]. Cook, J.K., Huggins, M.B., Orbell, S.J. Mawditt, K. and Cavanagh, D. (2001) Infectious bronchitis virus vaccine interferes with the replication of avian pneumovirus vaccine in domestic fowl. Avian Pathol., 30:233-242.
- [11]. Chabra, J.H. and peters, R.W. (1985) Humoral antibody response and assessment of protection following primary vaccination of chicken with maternal derived antibody against avian infectious bronchitis virus Res. Vet. Sci. 38: 14-21.
- [12]. Pakpinyo, S. and Sasipreeyajan, J. (1993) Efficacy of live La Sota Newcastle disease vaccine simultaneous vaccinated with various types of inactivated vaccine. Thairo. J. Vet. Med. 23(1): 35-74.
- [13]. Sharma, S.N. and Adlakha, S.C. (1994) *Text book of veterinary virology*. 1st. Edn. Vikas. Publishing Com. Pp: 286-296.
- [14]. Faris, B.H. (2006). Evaluation of different vaccination programs for inactivated Alum precipitated Newcastle disease virus vaccine in broiler chicks. M.Sc. Thesis – College of Veterinary Medicine – Baghdad University – Iraq.
- [15]. Montgomery, Y.R., Maslin, W.R. and Boyle, C.R. (1997) Effects of Newcastle disease vaccines and Newcastle disease/infectious bronchitis combination vaccines on the head-associated lymphoid tissues of the chicken. Avian Dis., 41(2): 399-406.
- [16]. Kindt, T.J., Goldsby, R.A. and Osborne, B.A. (2007) "Kuby Immunology". 6th Ed. Library of Congress, Publisher, S. Tenney, W.H. Freeman and Company, Printing and Binding, R.R. Donnelley New York, USA. Pp: 81-96.