



RNA-IN SITU HYBRIDIZATION, LMP-1, EBNA-2 FOR MOLECULAR LOCALIZATION OF LATENT EPSTEIN–BARR VIRUS EARLY REPEATS IN THYROID TISSUES WITH PAPILLARY CARCINOMA AND SIMPLE NODULAR GOITER

^{1*}Hind Ali Khamees, ²Saad H. Mohammed Ali, ¹Basim S. Ahmed & ¹Amer Alnajjarr

¹Department of microbiology, College of Medicine, Al-Mustansiriy University, Baghdad-Iraq

²Collage of health and medical technology.

*Corresponding author email: hindali10@yahoo.com

ABSTRACT

Epstein Barr virus (EBV) is ubiquitous virus which infects the majority of the human population and is the causative agent of many tumors. This virus expressed many proteins and it is associated with a variety of B-cell tumors. Recently many studies have suggested a causal relationship between EBV and differentiated thyroid cancer. In this study we investigated the association between EBV and papillary thyroid cancer. Aim of this study to found the correlation between EBV latency proteins in papillary thyroid cancer patients. Expression of (EBERs, LMP-1, EBNA-2) in thyroid tissue was evaluated in 30 patients and 30 simple nodular goiter as control by In situ hybridization and immunohistochemistry. Increased of EBERs, was significantly higher in papillary thyroid cancer patients compared with control patients. Our result suggests that these EBV proteins are accusation with papillary thyroid cancer.

KEY WORDS: Epstein-Barr virus, Latent membrane protein, EB nuclear protein, EB encoding –RNAs, In situ hybridization, papillary thyroid cancer, simple nodular goiter.

INTRODUCTION

There are various pathologic thyroid disorders /lesions that lead into an enlargement of thyroid gland, called as a goiter. Thyroid function may be normal (nontoxic goiter), over active (toxic goiter), or underactive (hypothyroid goiter) (Mulinda, 2014). Thyroid Cancer is a malignant tumor that is derived from either follicular (most of thyroid cancer) & parafollicular thyroid cells. These follicular cells give rise to both well-differentiated cancers (*i.e.*, papillary and follicular) and anaplastic thyroid cancer, while the C or parafollicular cell is the cell of origin for medullary thyroid carcinoma (MTC). (Udelsman, 2014) Recent studies have shown great association between viruses and cancer progression such as CMV, HIV and EBV. EBV There have been few studies regarding cancer progression from differentiated thyroid carcinoma to the undifferentiated one associated with possible involvement of Epstein-Barr virus (EBV) in this progression as in papillary carcinomas and undifferentiated carcinomas (Shimakage *et al.*, 2003). EBV was found in Non-Hodgkin lymphoma in patients with acquired immunodeficiency syndrome (AIDS) in 1982, in T-cell lymphoma in 1988, and in Hodgkin lymphoma in 1989. The virus has been associated with other malignancies (Spacek *et al.*, 2010). In 1991, scientists first noticed positivity of EBV in all tested sample of a rare but distinctive type of stomach cancer that had very similar characteristics to nasopharyngeal cancer (Shibata *et al.*, 1991). Epstein-Barr virus and it's the first virus described to be linked with the human pathogenesis of tumor. In 1968, EBV was recognized to be the

etiological factor of infectious mononucleosis. (Diehl *et al.*, 1968). EBV isolates are categorized as EBV type A and B (also known as type 1 and 2) depending on the sequence of the EBNA-2 gene. EBV-A shows more effective transforming activity in vitro than EBV-B type, and is mostly found in EBV-associated diseases (Martin *et al.*, 2014) The EBV-encoded RNA (EBER) are EBV encrypts small non-coding, non-polyadenylated RNA. (Rickinson & Kieff, 2007)EBER1 and EBER2, which are correspondingly 167 and 172 nucleotides long, are transcribed by RNA polymerase III with 54% sequence homology exists between these two RNAs. EBERs are castoff as target molecules for recognition of EBV-infected cells in tissues in situ hybridization and are a reliable marker of the presence of EBV, since by are copiously expressed in latently EBV-infected cells. EBERs have been shown to enhance the growth and proliferation of epithelial cell lines derived from NPC and GC. (Tsang *et al.*, 2012). EBNA-2 is essential for EBV-mediated growth transformation. (Palermo *et al.*, 2008) EBNA-LP and EBNA-2 are firstly expressed viral genes, then followed by the other latency genes, The role of EBNA-2 in B-cell growth transformation is closely related to transactivation of cellular and viral gene expression such as expression of the LMP genes and B-cell genes, including CD23, CD21 and c-fgr, thus EBNA-2 finally govern the activation of the resting B-cell, cell cycle entry and propagation of the growth transformed cells.LMP1 is a confirmed oncogene in rodent fibroblasts. Where along with the nuclear proteins EBNA1, EBNA2, and EBNA3a and c, Latent membrane protein 1 (LMP1), a main viral

protein expressed during EBV infection, LMP1 is essential for transformation of human B cells (Brennan *et al.*, 2001) LMP1 is mandatory for oncogenesis of the B cell tumors (Dirmeier *et al.*, 2003) and associated with increased frequency of lymphomas representing that LMP1 can be oncogenic in vivo, (Lambert *et al.*, 2007). LMP1 itself is an integral membrane protein comprising six transmembrane-spanning domains and a long C-terminal tail (Li *et al.*, 2003). LMP1 signal transduction is mediated over the intracellular tail of LMP1 (Stunz *et al.*, 2004). Activation of these cellular signaling paths by LMP1 results in a variety of phenotypic changes related with malignancy, including the up-regulation of anti-apoptotic genes and the initiation of cellular IL-10. (Snow *et al.*, 2006)

MATERIALS & METHODS

This study was designed as retrospective one. Sixty selected formalin fixed, paraffin embedded thyroid tissue blocks were enrolled and were distributed on the following groups: I- Thirty tissue blocks from patients with papillary thyroid cancer. II- Thirty tissue blocks with benign thyroid lesions as control thyroid tissues group. The age of these patients were ranged from 10 to 75 years. Malignant and normal thyroid tumors tissue blocks were collected from the archives of histopathology laboratories of different general hospital including AL-Yarmouk Teaching Hospital (Baghdad), Baghdad Medical City Teaching Hospital as well as many private laboratories in Baghdad. Generously helped as and are kindly thanked in the present dedication.

In situ hybridization for detection of EBV by EBERs

The presence of certain nucleic acid sequences in cells or tissue can be detected with in situ hybridization using labeled RNA Probes. The hybridization results in duplex formation of sequences present in the test object and the specific gene probe.

It is indirectly detected using an enzyme-conjugated antibody targeting the tags: the enzymatic reaction of chromogenic substrates leads to the formation of a colour precipitate that is visualized by light microscopy.

Procedure

- A: Slides preparation: Serial thin sectioning of (4 m) thickness was done for each paraffin-embedded tissue block and sticking the sections on charged slides. Paraffin sections were deparaffinized (Dewax) in oven at 60°C overnight.
- B: Deparaffin and rehydration was done by serial steps in glass staining jars containing the following:
- Xylene (100%) for 15 minutes (two times).
 - Ethanol (100%) for 5 minutes (two times).
 - Ethanol (95%) for 5 minutes (one time).
 - Ethanol (70%) for 5 minutes (one time).
 - Distilled water for 5 minutes. (one time)
 - Dry the slides for 5 min at 37C.
 - Wash the slides 3 time by 1xPBS 5 min.
- C: Add pepsin solution was applied in tissue and incubated in (30-40) in humidity chamber at 37C and washing the slide for 5 min and dry section.
- D: Denaturation and Hybridization:
- Vortex the probe and pipette (5-8) µl Probe to the samples.

- Cover slip and denature the slide in humidity chamber in 75c for 5 min.
 - Incubate slide overnight in 55c or 60 min.
- E: Post-hybridization and Detection:
- Removing the rubber cement carefully.
 - Preparing two wash buffer in jar (in room temperature and in 55C) for 5 minutes.
 - Rinsing the slides in wash buffer at room temperature for 5 minutes and then washing the slides in wash buffer at 55c for 5 minutes.
 - Washing the slides in wash buffer at RT for 5 minutes.
 - NBT/BCTP was applied and incubated for 90-120 minutes at 37C in a humidity chamber.
 - Washing 3 times by Deionized water or distilled water for 5 minutes.
 - Adding nuclear fast Red for 2 minutes.
- F: Dehydration:-Dehydrating the sections serial concentration of alcohol:
- Ethanol: 70%, 95%, 100% (one time), 100% (2time) and 2 min. for each concentration and finally incubate in xylene 100% for two minutes.
- E: Mounting: Add mounting medium (DPX) and Read the slide under light microscopy.

Immunohistochemistry

Latent membrane protein -1 and EBNA-2

I- principle of the test:

The samples were rehydrated and treated with protein blocking agent to reduce non-specific binding of antibodies. The tissues were incubated with Primary AB to binds to specific Ag, Biotinylated secondary Ab to binds to the primary Abs, Streptavidin peroxidase reagent to binds to secondary Ab. The streptavidin binds to biotin on the secondary Abs: then peroxidase serves as the indicator enzyme. The last step addition of peroxidase substrate (hydrogen peroxide) and colored chromogen resulted in the formation of colored in the tissue Ag.

II- Procedure: All steps were done at room temperature.

A-Dewaxing: The same method of dewaxing used with ISH was also applied for immunohistochemistry.

B-REHYDRATION :

- Add Xylene: 100% for 15 minutes 2 times
- Add Ethanol: 100 % for 5 minutes 2 times
- Add Ethanol: 95% for 5 minutes .
- Add Ethanol: 70% for 5min .
- Wash in D.W for 5min
- Air Dry section for 5 minuter at 37C .

C: Add enough drops of hydrogen peroxide Block to cover the section incubate 10 min .Wash 2 times in buffer and Air dry section.

D: - Retrieval

Unraveling antigenic epitopes by retrieval methods is important for successful immunohistochemically staining and detection of protein .Slides were placed in bath containing retrieval solution 1ml of citric acid +100ml D.W was added and boiled in 95C/PH=6 for 20min.

- Washed with Buffer for 5min

E: Power block :

Enough drops of protein Block were added to cover the sections for 10min in 25C and slides were put in humidity chamber .Then slides were drained for 5 minute.

- Slides were air –dried.

F-Primary antibody:

The slides were covered with enough drops of ready to use primary (anti LMP-1 and Anti EBNA2) after that incubated for overnight in a humidity chamber at RT .After that all the slides were rinsed with PBPs for 5 minutes

G- Apply secondary antibody :

Biotinylated coat Anti-mouse was added for 30-45min. and buffer was washed for 5 min and was dried.

H-Add streptavidin peroxidase reagent :The slides were covered with enough drops of streptavidin peroxidase and incubated for 15 minutes at RT and slides was washed for 5 minutes.

I-Chromogen :Enough drops of DAB chromogen were applied in dark room (30µlDAB chromogen +1.5mlDAB substrates) for 10 min and buffer for 5min and slides were dried.

J:Hematoxylin counter stain :Enough drops of haematoxylin were added for 2minutes and Washed by tap water.

K: Dehydration:-dehydrated the sections by using series concentration of alcohol: (100%,95%,70%) %one time) and 100% (two times), two minutes for each solution ; finally incubation in xylene 100% for two minutes .

M: Mounting: Enough drops of mounting media were placed to cover the section and let dry over night at RT .

- DPX +cover slip.

- Light microscopy.

Statistical analysis

Data were translated into a computerized database structure. The database was examined for errors using range and logical data cleaning methods, and inconsistencies were remedied. An expert statistical advice was sought for. Statistical analyses were done using IBMSPSS version 21 computer software (Statistical Package for Social Sciences) in association with Microsoft Excel 2013.

RESULTS

Viral markers

After application and analysis of ISH and IHC, the results of EBV in PTC cases are shown in table (1). The total percentage of EBV was estimated from the percentage of EBV- EBERs and / or EBV- EBNA-2 and / or EBV-LMP 1 in each of the 60studied thyroid specimens, regarding these positive EBV results , individually or collectively, as a single positive EBV result .As such, the percentage of EBV results in the total group of PTC was (50%) while the percentage in the total SNG group was (10.0%). The magnitude of expression of each of each tested markers was measured in 2 different ways. The first one is a scoring system with ordinal categories ranging between 1 to 4. The second one is an intensity measure with 3 ordered categories for a positive stain.

TABLE 1: The total EBV in studied groups

Total EBV*	Studied groups		Pearson Chi-Square (P-value)
	SNG	PTC	
Positive	N 3 % 10.0%	15 50.0%	P = 0.003
Negative	N 27 % 90.0%	15 50.0%	HS**
Total	N 30 % 100.0%	30 100.0%	(P<0.01)

* The total percentage of EBV was estimated from the percentage of EBV- EBERs and / or EBV- EBNA 1 and / or EBV-LMP1

**HS = Highly Significant difference (P<0.01), SNG= Simple nodular goiter, PTC= Papillary thyroid cancer.

TABLE 2: Total Results of ISH for EBV- EBERs Detection in the Studied Groups

EBERs test	Studied groups		Person Chi-Square (p-value)
	SNG	PTC	
Negative	N 29 % 96.7%	21 70.0%	P = 0.021
Positive	N 1 % 3.3%	9 30.0%	S*
Total	N 30 % 100.0%	30 100.0%	(P<0.05)

*S = Significant difference (P<0.05).

The results of in situ hybridization for detection EBV-EBERs in PTC tissues are shown in table (2). The percentage of positive -EBV EBERs-ISH reactions in the total group of PTC was (30%), and in SNG tissues was (3.3%). The statistical analysis shows significant differences among the studied groups (p<0.05).The results of immunohistochemistry for detection EBV EBNA-2 in PTC tissues are shown in table (4) and figure (1) the percentage of positive – EBNA-2 IHC reactions in the

total group of PTC was (20%), and in SNG tissues was (6.7%). The statistical analysis shows non- significant differences among the studied groups (p value is more than 0.05).The results of immunohistochemistry for detection EBV – LMP-1 in PTC tissues are shown in table (3) and figure (4) The percentage of positive -EBV– LMP-1- IHC reactions in the total group of PTC was (43.3%), and in SNG tissues was (6.7%).

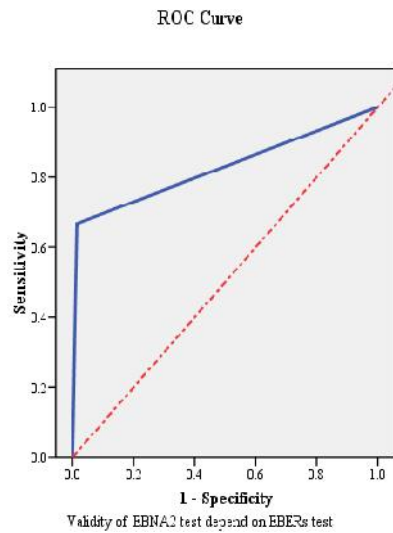


FIGURE 1: Curve evaluation of EBV-EBNA-2 marker depend on EBERs test

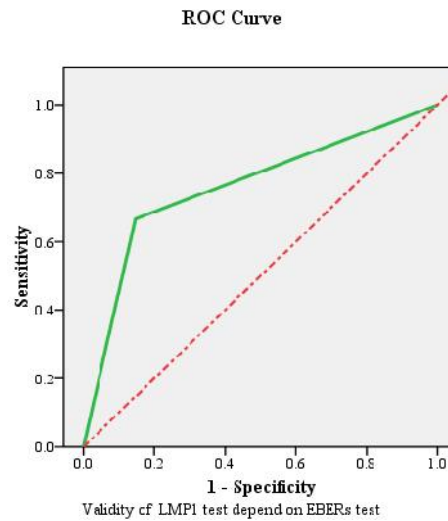


FIGURE 2: Curve evaluation of EBV-LMP1 marker depend on EBERs test

TABLE 3: Total EBNA-2- IHC signal results in studied groups

EBNA-2 test	Studied groups		Pearson Chi-Square (P-value)
	SNG	PTC	
Negative	N 28	24	P = 0.261
	% 93.3%	80.0%	
Positive	N 2	6	NS*
	% 6.7%	20.0%	
Total	N 30	30	(P>0.05)
	% 100.0%	100.0%	

*NS = Non Significant difference (P>0.05)

TABLE 4: Total LMP-1- IHC signal results in studied groups

LMP-1 test	Studied groups		Pearson Chi-Square (P-value)
	SNG	PTC	
Negative	N 28	17	P = 0.003
	% 93.3%	56.7%	
Positive	N 2	13	HS*
	% 6.7%	43.3%	
Total	N 30	30	(P<0.01)
	% 100.0%	100.0%	

*HS = Highly Significant difference (P<0.01).

TABLE 5: Correlation between EBV markers

Spearman's rho	Total EBV	EBERs Scores
EBERs Scores	r .699(**)	
	P-value .000	
EBNA2 Scores	r .584(**)	.749(**)
	P-value .000	.000
LMP1 Scores	r .858(**)	.486(**)
	P-value .000	.000

The statistical analysis shows highly significant differences among the studied groups (p<0.05). In table (4.16) shows or proved there was a strong positive relationship with highly significant difference between EBV markers scoring (EBNA2, LMP1) according to EBERs score on the grounds EBERs is the best marker to diagnosis EBV infection as well as EBNA2 and LMP1 EBNA2{r=0.584, pvalue=0.000 (P<0.05) H.S} LMP1

{r=0.858, p value=0.000(P<0.05) H.S}. Receiver operating characteristic (ROC) curve evaluation (that including sensitivity, specificity, P.P.V., N.P.V. and accuracy) of LMP1 and EBNA- test results depending on EBERs test results. The evaluation reveals that EBNA-2 results were higher specificity (98.7%), and sensitivity (66.7) as well as with highly significant differences when compared with EBERs results {P=0.000, P<0.01}. Also

evaluation reveals of LMP1 show lower results were specificity (85.3%) and the same sensitivity (66.7%), as

well as with highly significant differences when compared with EBERs results { $P=0.002$, $P<0.01$ }.

TABLE 6: ROC area for the three selected markers and indices when used as test to diagnose EBV

Tests	Tests						P-value
	Area Under the curve	Sensitivity (%)	Specificity (%)	P.P.V. (%)	N.P.V. (%)	Accuracy (%)	
EBNA2 test	.827	66.7	98.7	90.9	93.7	93.33	0.00 HS
LMP1 test	.760	66.7	85.3	47.6	92.8	82.22	0.002 HS

Desiccation

Viral markers

EBERs

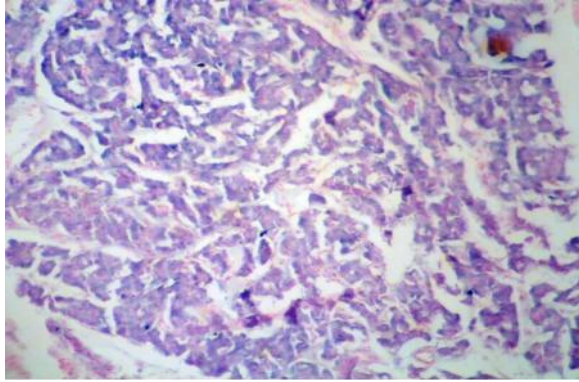
Epstein- Barr virus with variety in B-cell tumors including Burkitt's lymphoma, Hodgkin lymphoma, human immunodeficiency virus, post transplantation lymphoma disorder and Chronic lymphocytic leukemia. Few studies reported that papillary thyroid cancer had evidence of EBV infection by In situ hybridization for EBERs and detection of EBV-encoded EBER transcripts is considered the gold standard for localizing latent EBV in tissue samples, as EBER transcripts are universally expressed in all EBV-associated tumors (Tsimberidou *et al.*, 2006; Cohen *et al.*, 2014).

The presence of EBERs has been shown to correlate with progressive or accelerated clinical course including transformation to Richter's large cell lymphoma (Ansell *et al.*, 1999, Tsimberidou AM *et al.*, 2006). However EBERs is also found in quiescent EBV latency where no protein is produced and that may be a suboptimal marker for proliferation or transformation capability. The present results and these relative speculations are supported by the findings of Shimakage *et al.* (2003) who studied comparatively 10 papillary thyroid carcinomas and 11 undifferentiated thyroid carcinomas to examine the relationship and the role of EBV infections of PTC cases (as a differentiated type of thyroid cancers) and their progression to undifferentiated thyroid cancers. Those authors have found that EBV appeared to involve all (100%) the thyroid carcinomas examined irrespectively to their pathologic differentiation degrees where the protein expression of two important transforming genes (namely EBNA-2 and LMP1) in their studied tissues were stronger in undifferentiated thyroid cancers than in their papillary (differentiated) carcinomatous counterparts. The present study while enrolling a series of differentiated thyroid carcinomas (*i.e.* papillary thyroid cancers) got its expected importance in the subject of viral roles in relation to cancers (*i.e.* viral carcinogenesis) from many evidences among them: (first) most of the tissues of undifferentiated thyroid carcinomas have developed from a back-ground of a differentiated carcinomas such as follicular or papillary thyroid tumors, which have been in those patients for many years (Akhtar, 2004). Second: those undifferentiated thyroid cancers are not amenable for either surgical resection or any types of the known chemotherapeutic regimens. As such, these facts criticized many scientific researchers for understanding the transformation mechanisms which might in turn help in devising therapeutic and preventive strategies for such cancers.

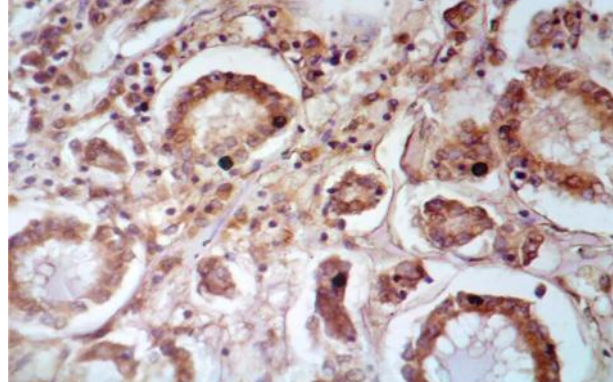
Shimakage *et al.* (2003) regarding the negative detection rates of these markers in their studied series of thyroid tissues obtained from either benign thyroid diseases or in those cell lines which were derived from undifferentiated thyroid carcinomas as well as from squamous cell carcinomas. From these results we can conclude that each of these markers of EBV (especially EBNA2 followed by LMP1) of could be used with a relative efficacy for diagnosis of latent EBV infection, at least, In our series of PTC cases studied here in reaching the efficacy and importance of the presence of EBERS in all types of cancers that are associated and/ or virally related or caused by EBV. It was stated that if these EBV types have a causal role in NPC, it is reasonably expected that this event might occur as an early process and that EBV would be found in at least some normal nasopharyngeal tissues (Thiago *et al.*, 2008). However, previous studies which were published on thyroid carcinomas have failed to reveal any evidences of EBV infection in the examined tissues. In this respect, Kijima *et al.* (2001) have studied a series of 45 thyroid papillary carcinomas using in situ hybridization and failed to localize ISH-signals for EBER1 probe. In addition, Ludrikove *et al.* (2001) reported that none of the 12 studied cases of oncocytic papillary carcinomas of thyroid have revealed ISH-signals for EBER1 probe, too. These disparities in the currently obtained as well as the previous results might be related to differences in the sensitivities of the probe used for detection of EBV infection and urge for an additional studies using larger numbers as well as different types, grades and stages of the enrolled thyroid cancer cases for confirming and further elaborating the role of EBV infection in the pathogenesis and progression of thyroid carcinomas. For the shortage of articles that searching on the relation of EBV infection with different thyroid diseases, tumors or cancers, thus and by analogy, the present study (and in turn the obtained results) will be compared with the rates of EBV infections in another relating and / or anatomical nearby or histopathologically similar lesions and /or cancers that have also shared different EBV- markers in their examined tissues. In a meta-analysis study of a respective bulk of studies (38 published articles) have studied the relationship between thyroid cancer and those patients with a history of Hashimoto's thyroiditis. In this respect, Hashimoto's thyroiditis was found more likely to be histologically detected around the papillary cancer (40%) than around the benign thyroid nodules (21%) in females patients (23%) compared to their male counterparts (11%) and in the papillary thyroid cancer type (17%) as compared to

other types of thyroid cancers (8%) (Lee et al, 2013). In addition, Janegova *et al.* (2015) in their study have found that the immunohistochemical positivity-rates of EBV was demonstrated only in samples of Hashimoto's thyroiditis, where in 8 tissues out of 26 (34%) obtained from Hashimoto's thyroiditis there was a cytoplasmic expression

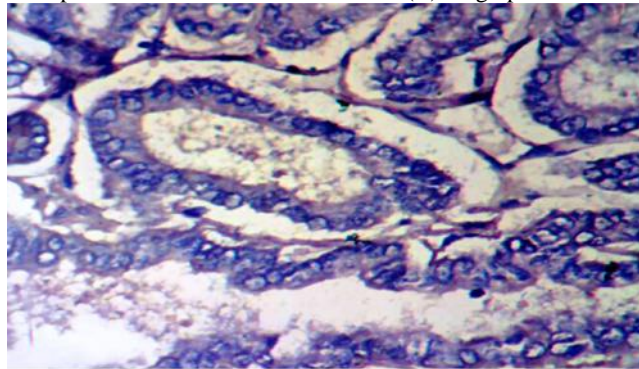
of viral latent membrane protein 1 (LMP1). Using in-situ hybridization methods for the detection of EBERS, we have found that in 21 (80%) of 24 of Hashimoto's thyroiditis cases their EBV-positive cells have showed nuclear expression for EBERS.



(A) Low power EBERS positive in cancer



(B) High power EBNA2 positive in normal tissue



(C) High power LMP1 positive in cancer

High grade, showing strong nucleic staining of EBERS by ISH (B and C) showed the positive result of (LMP-1 and EBNA-2) by immunohistochemical staining respectively, X100

These studies could support our results in some way or other to explain why those higher percentages of detection of EBV in our series of cases of papillary thyroid cancers might be related to the possibility of presence of Hashimoto's disease that might surrounded many PTC-tissues. Kasprzak *et al.* (2007) have noticed from their study that the B lymphocytes are the main target cells for EBV and that this EBV can also infect T lymphocytes and epithelial cells. Kasprzak *et al.* (2007) have also observed that more than 90% of all primary thyroid lymphomas have developed in patients with a history of Hashimoto's disease while on the contrary, none of the control goiters demonstrated EBERS expression. In this respect, the study done by Janegova and his workers (2015) has demonstrated that the expression of EBV-associated products were both detected in the infiltrating lymphocytes in Hashimoto's thyroiditis as well as in thyroid follicular cells.

CONCLUSION

In situ hybridization techniques was successfully established and employed in the detection of EBV in papillary thyroid cancer cases. Immunohistochemistry is of valuable value in the diagnosis of LMP1 and EBNA2

RECOMMENDATION

- I recommend to study large sample size of papillary thyroid cancer and other type of thyroid cancer like follicular, medullary, anaplastic thyroid cancer to improve the role of EBV.
- To elucidate the role of different EBV proteins that are responsible for switching from latency states to active EBV replication such as BZLF1 and /or RTA in the tissue from thyroid carcinoma especially papillary thyroid cancer
- Study the role of Bcl-2 which association with EBNA-2 and LMP-1 activation and cell proliferation.
- Detect the integration of LMP-1 in cellular nucleic acid by PCR and sequencing assay.

REFERENCES

- Diehl, V., Henle, G., Henle, W. and Kohn, G. (1968) Demonstration of herpes group virus in cultures of peripheral Leukocytes from patients with infectious mononucleosis. *Journal of virology*, 2(7):663-9.
- Shibata, D., Tokunaga, M., Uemura, Y., Sato, E., Tanaka, S. and Weiss, L.M. (1991) Association of Epstein-Barr virus with undifferentiated gastric carcinomas with intense

- lymphoid in filtration. lymphoepithelioma-like carcinoma. *Am.J.pathol.*139(3):469-74.
- Brennan, P. (2001) Signalling events regulating lymphoid growth and survival. *Semin. cancer. Biol.* (11):415-421.
- Dirmeier, U.B., Neuhier, E., Kilger, G., Reisbach, M.L., Sandberg, and Hammerschmidt, W. (2003) Latent membrane protein-1 is critical for efficient growth transformation of human B cells by Epstein-Barr virus. *Cancer Res.*(63):2982-2989.
- Lambert, S.L. and Martinez, O.M. (2007) Latent membrane protein-1 of EBV activates phosphatidylinositol 3-kinase to induce production of IL-10. *J. Immunol.* (179) :8225-8234.
- Li,H.P. & Chang, Y.S.(2003)Epstein- Barr virus latent membrane protein -1 structure and functions. *J. Biomed. Sci.* (10):490-504.
- Stunz, L.L., Busch, L.K., Munroe, M.E., Sigmund, C.D., Tygrett, L.T., Waldschmidt, T.J. and Bishop, G.A. Expression of the cytoplasmic Tail of LMP-1 in mice induces hyper activation of B-lymphocytes and disordered lymphoid architecture. *Immunity*, (21):255-266.
- Martins, M.B., Marcello, M.A., Batista, F.D., Cunha, L.L., Morari, E.C., Soares, F.A., Vassallo, J. and Ward, L.S. (2014) CD8+TIL Recruitment may Recruitment tumors. *Jornal of Immunology Reseach*, (921864).8.
- Rickinson, A.B. and Kieff, E. (2007) Epstein-Barr virus. In *Knipe DM and Howley PM. Fields Virol. Philadelphia: Walters Kluwer/Lippincott*, p. 2655–2700.
- Tsang, C.M., Yip, Y.L., Lo, K.W. (2012) Cyclin D1 overexpression supports stable EBV infection in nasopharyngeal epithelial cells. *Proc. Natl. Acad. Sci. USA* 109: E3473–3482.
- Udelsman, R. (2014) "Thyroid Cancer". *Annual Review of Medicine* 65: 125–137.
- Shimakage, M., Kawahara, K., Sasagawa, T., INOUE, H., Yutsudo, M., Yoshida, A. and Yanoma, S. (2003) Expression of Epstein-Barr virus in thyroid carcinoma correlates with tumor progression. *Clinical Research. Institute*, (3):1170-1176.
- Snow, A.L., Lambert, S.L., Natkunam, Y., Esquivel, C. O., Krams, S.M. and Martinez, O.M. (2006) EBV can protect latently infected B cell lymphomas from death receptor-induced apoptosis. *J. Immunol*, 2006; 177: 3283–3293. .
- Kijima,Y., Hokita, S. and Takano, S. (2001) Oncocytic papillary carcinoma with lymphoid stroma (Warthin-like tumor) of The Thyroid. A distinct entity with favourable prognosis. *histopathology*(39):17-24.(2001). *J. Med. Vivo.* (64):513-518.
- Ludvikova, M., Ryska, A., Korebecna, M., Rydlova, M. and Michal, M. (2001) Oncocytic papillary with lymphoid stroma (warthin-like tumor) of the thyroid: *Histopathology* 39:17.24.
- Ansell, S.M., Li, C.Y., Lloyd, R.V., Phylly, R.L. (1999) Epstein-Barr virus infection in Richter's transformation. *Am J Hematol*: 60(2):99-104.
- Cohen, M., Na. Metrebian, De Matteo, E., Preciado, M.V. and Chabay, P.A. (2014) Epstein-Barr virus-positive diffuse large B-cell lymphoma association is not only restricted to elderly patients. *Int. J. Cancer*, 135, 2816–2824. rbaitz M, F
- Tsimberidou A.M. , Keating M.J. Bueso-Ramos CE , & Kurzrock R .(2006) .Hodgkin transformation of chronic lymphocytic leukemia: the M.D. Anderson Cancer Center experience, 107(6):1294-302, 2006.
- Tsimberidou, A.M., Keating, M.J., Bueso-Ramos, C.E., and Kurzrock, R. (2006) Epstein-Barr virus in patients with chronic lymphocytic leukemia: a pilot study. *Leuk Lymphoma*: 47(5): p. 827-36.
- Tselis, A. & Jenson, H.B. (2006) Epstein-Barr Virus (*Infectious Disease and Therapy*). *Informa Healthcare*, 12(10): p. 1625.
- Akhtar, M. (2004) Epstein-Barr virus may have a role in progression of thyroid carcinoma. *Adv. Anat. Pathol* 11 (3):173.
- Mulinda, J.R. (2014) Goiter: Back ground, patho physiology *Epidemiology.Medscape*.120034.
- Spacek, M., Hubacek, P., Markova, J., Zajac, M., Vernerova, Z., Kamaradova, K., Stuchly, J. and Kozak, T. (2010). *APMIS*. 119(1):10-6.
- Palermo, R.D., Webb, H.M., Gunnell, A. and west, M.J. (2008) Regulation of transcription by the Epstein-Barr virus nuclear antigen EBNA2. *Biochem. Soc. Trans.* 36 (pt4) :625-8.
- Thigo, M.M., Oliveria, L.C., Yamamoto, L., DelNegro, G.M.B. and okays, T. (2008) Epstein-Barr virus Nuclear Antigen-2 Detection and typing in immunocompromised children correlated with lympho proliferative Disorder biopsy finding. *The Brazilian Journal of infectious diseases*. 12(3):186-191.
- Janegova, A., Janeqa, P., Rychly, B., Kuracinova, K. and Babol, P. (2015) *Endokrynol pol.*66(2):132-6.
- Lee, H.J., Kim, Y., Choi, J.W. and Kim, Y.S. (2013) The association between papillary thyroid carcinoma and histologically proven Hashimoto's thyroiditis: ameta-analysis, *Eur. J.Endocrinol.*168 (3):343-9.
- Kasprzak, A., Spachacz, R., Wachowiak, J., Stefanska, K. and Zabel, M. (2007) Epstein-Barr virus (EBV) infecton in B-cell non-Hodgkins Lymphomas in children virus latency and its correlation with CD21 and CD23 molecules. *Folia. Histochem. cytobiol.*45(3):169-79.